



Brain disorders mimicking encephalitis, but it's not infectious encephalitis

Prof. Pierre TATTEVIN


Maladies Infectieuses et Réanimation Médicale
Hôpital Pontchaillou, CHU Rennes



Déclaration de liens d'intérêt avec les industries de santé en rapport avec le thème de la présentation (loi du 04/03/2002) :

Intervenant : Tattevin Pierre

Titre : Non infectious encephalitis

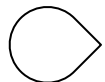


Consultant ou membre d'un conseil scientifique

OUI



NON




Conférencier ou auteur/rédacteur rémunéré d'articles ou documents

OUI



NON




Prise en charge de frais de voyage, d'hébergement ou d'inscription à des congrès ou autres manifestations

OUI



NON



Investigateur principal d'une recherche ou d'une étude clinique

OUI



NON

Case Definitions, Diagnostic Algorithms, and Priorities in Encephalitis: Consensus Statement of the International Encephalitis Consortium

A. Venkatesan,¹ A. R. Tunkel,² K. C. Bloch,^{3,4} A. S. Luring,⁵ J. Sejvar,⁶ A. Bitnun,⁷ J-P. Stahl,⁸ A. Mailles,⁹ M. Drebot,¹⁰ C. E. Rupprecht,¹¹ J. Yoder,¹² J. R. Cope,¹² M. R. Wilson,^{13,14} R. J. Whitley,^{15,16,17,18} J. Sullivan,¹⁹ J. Granerod,²⁰ C. Jones,^{21,22} K. Eastwood,²³ K. N. Ward,^{20,24} D. N. Durrheim,^{25,26} M. V. Solbrig,²⁷ L. Guo-Dong,²⁸ and C. A. Glaser,²⁹ on behalf of the International Encephalitis Consortium

Table 1. Diagnostic Criteria for Encephalitis and Encephalopathy of Presumed Infectious or Autoimmune Etiology

Major Criterion (required):

Patients presenting to medical attention with altered mental status (defined as decreased or altered level of consciousness, lethargy or personality change) lasting ≥ 24 h with no alternative cause identified.

Minor Criteria (2 required for possible encephalitis; ≥ 3 required for probable or confirmed^a encephalitis):

Documented fever $\geq 38^{\circ}$ C (100.4° F) within the 72 h before or after presentation^b

Generalized or partial seizures not fully attributable to a preexisting seizure disorder^c

New onset of focal neurologic findings

CSF WBC count ≥ 5 /cubic mm^d

Abnormality of brain parenchyma on neuroimaging suggestive of encephalitis that is either new from prior studies or appears acute in onset^e

Abnormality on electroencephalography that is consistent with encephalitis and not attributable to another cause.^f

Case Definitions, Diagnostic Algorithms, and Priorities in Encephalitis: Consensus Statement of the International Encephalitis Consortium

A. Venkatesan,¹ A. R. Tunkel,² K. C. Bloch,^{3,4} A. S. Luring,⁵ J. Sejvar,⁶ A. Bitnun,⁷ J-P. Stahl,⁸ A. Mailles,⁹ M. Drebot,¹⁰ C. E. Rupprecht,¹¹ J. Yoder,¹² J. R. Cope,¹² M. R. Wilson,^{13,14} R. J. Whitley,^{15,16,17,18} J. Sullivan,¹⁹ J. Granerod,²⁰ C. Jones,^{21,22} K. Eastwood,²³ K. N. Ward,^{20,24} D. N. Durrheim,^{25,26} M. V. Solbrig,²⁷ L. Guo-Dong,²⁸ and C. A. Glaser,²⁹ on behalf of the International Encephalitis Consortium

Table 1. Diagnostic Criteria for Encephalitis and Encephalopathy of Presumed Infectious or Autoimmune Etiology

Major Criterion (required):

Patients presenting to medical attention with altered mental status (defined as decreased or altered level of consciousness, lethargy or personality change) lasting ≥ 24 h with no alternative cause identified.

Minor Criteria (2 required for possible encephalitis; ≥ 3 required for probable or confirmed^a encephalitis):

Documented fever $\geq 38^{\circ}$ C (100.4° F) within the 72 h before or after presentation^b

Generalized or partial seizures not fully attributable to a preexisting seizure disorder^c

New onset of focal neurologic findings

CSF WBC count ≥ 5 /cubic mm^d

Abnormality of brain parenchyma on neuroimaging suggestive of encephalitis that is either new from prior studies or appears acute in onset

Abnormality on electroencephalography that is consistent with encephalitis and not attributable to another cause.^f

In Search of Encephalitis Etiologies: Diagnostic Challenges in the California Encephalitis Project, 1998–2000

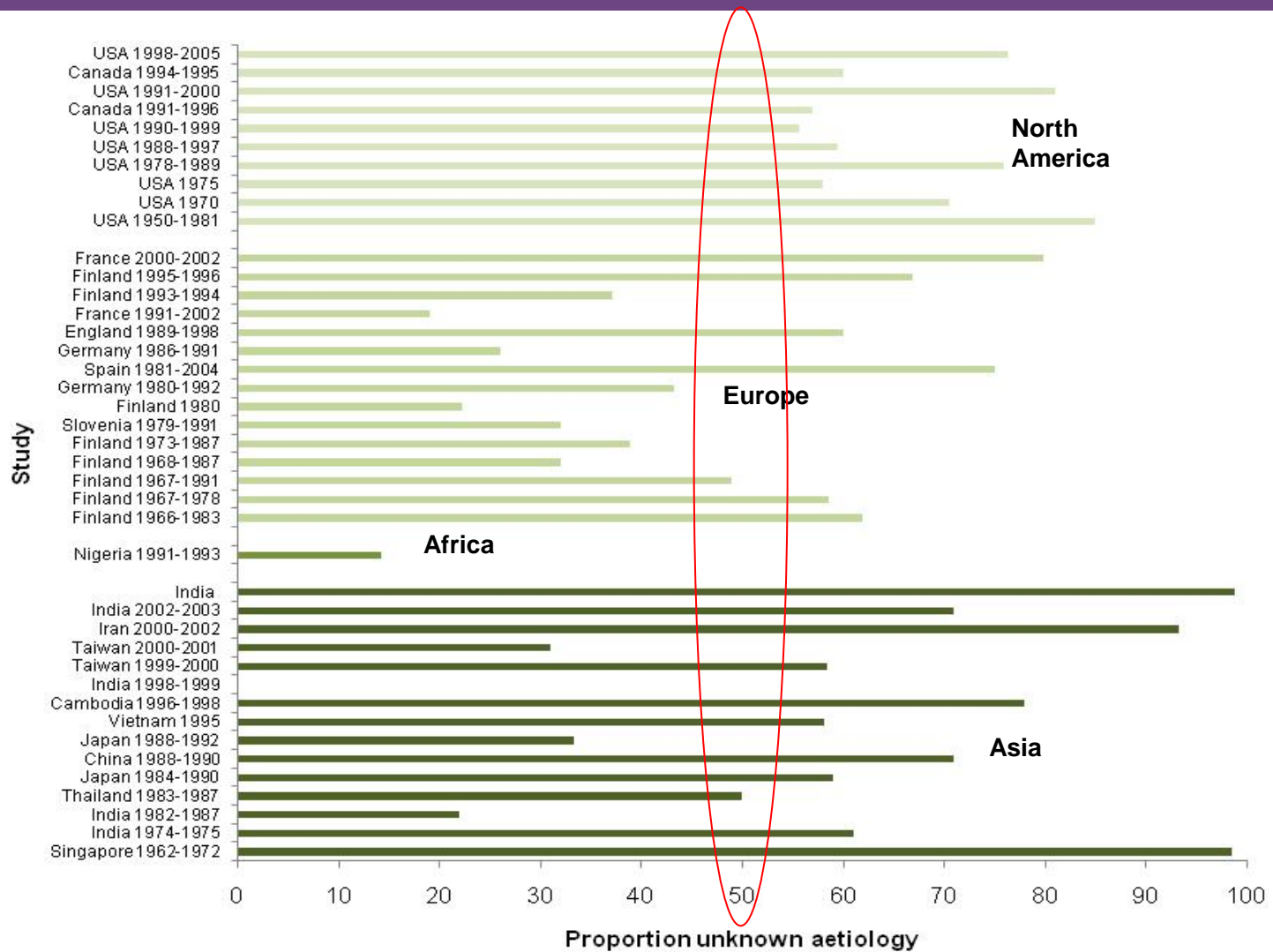
Carol A. Glaser,¹ Sabrina Gilliam,¹ David Schnurr,¹ Bagher Forghani,¹ Somayeh Honarmand,¹ Nino K. Marc Fischer,³ Cynthia K. Cossen,¹ and Larry J. Anderson²

- Prospective, multidisciplinary project, dedicated funding
- Systematic collection of clinical data (incl. exposures)
- Broad range of routine testing in expert labs

=> First 334 patients => 208 (62%) unexplained

Routine test (specimen), result	No. of positive results/total no. of tests
PCR (CSF and/or brain)	
Enterovirus	5/323
Herpes consensus ^a	17/320
Antibody (acute-phase serum)	
EBV	4/325
Measles	2/266
<i>Mycoplasma pneumoniae</i>	11/309
St. Louis encephalitis	0/331
Western equine encephalitis	0/331
West Nile virus	0/119
Enterovirus	13/319
Antibody (acute- and/or convalescent-phase serum)	
<i>Bartonella henselae</i>	7/203
<i>Chlamydia species</i>	6/184
HSV	17/307
<i>M. pneumoniae</i>	5/207
VZV	10/307
St. Louis encephalitis	0/208
Western equine encephalitis	0/208
West Nile virus	0/117
Antibody (CSF)	
Measles	2/128
Enterovirus	1/125
Virus isolation	
Isolate from brain specimen	0/15
Isolate from CSF specimen	0/68
Isolate from respiratory specimen	9/170
Isolate from stool specimen	3/165

Encephalitis of unknown origin

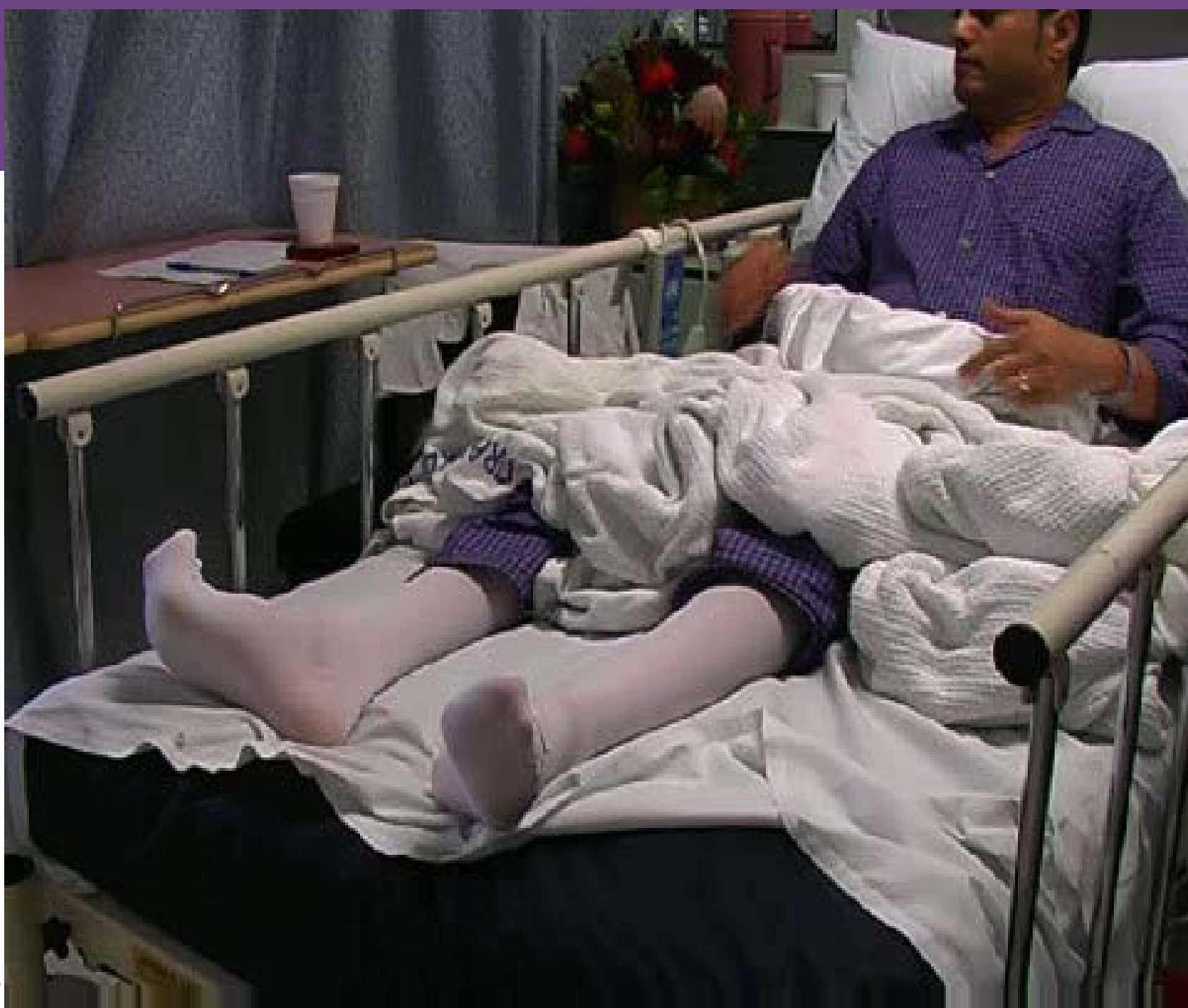

Encephalitis of unknown origin: what could it be ?

1. Infectious encephalitis, unknown pathogen
=> new diagnostic tools (e.g. next generation sequencing)
2. Infectious encephalitis, pathogen known, but not diagnosed
=> clinical skills / more sensitive diagnostic tools /
adequate sampling
3. Non-infectious encephalitis, the 'mimickers'

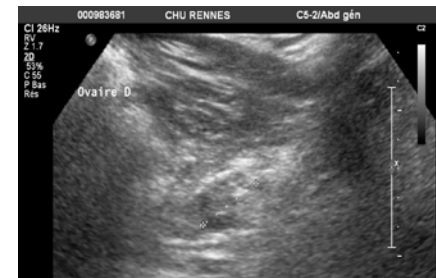Case 1

- **32 year-old women**
- **Feb. 2012**
 - Diarrhea, headache, abdominal pain, fever
- **March 2012 (7 days)**
 - Memory loss, psychiatric disorders (psychotic)
 - Dyskinesia (see movie), seizures
- **Diagnostic workout**
 - Brain imaging unremarkable
 - CSF: 100 cells/mm³, 100% lymphos, prot. 1 g/L



Anti-NMDA receptor encephalitis

- **#1 cause of encephalitis in young adults**
 - 549/577 cases < 45 years / Female-to-male ratio 4:1
 - Ovarian teratoma in 50% of women > 12 years
- **Anti-NMDAr Ab in CSF (IgG anti-GluN1)**
- **Treatment**
 - Corticosteroids / IgIV or plasmapheresis
 - Rituximab / cyclophosphamide + **treatment of teratoma**
- **Prognosis**
 - Usually good, but **recovery very slow**



A clinical approach to diagnosis of autoimmune encephalitis

Francesc Graus, Maarten J Titulaer, Ramani Balu, Susanne Benseler, Christian G Bien, Tania Cellucci, Irene Cortese, Russell C Dale, Jeffrey M Gelfand, Michael Geschwind, Carol A Glaser, Jerome Honnorat, Romana Höftberger, Takahiro Iizuka, Sarosh R Irani, Eric Lancaster, Frank Leypoldt, Harald Prüss, Alexander Rae-Grant, Markus Reindl, Myrna R Rosenfeld, Kevin Rostásy, Albert Saiz, Arun Venkatesan, Angela Vincent, Klaus-Peter Wandinger, Patrick Waters, Josep Dalmau

Rationale

- The most active area of research in the field of encephalitis
 - New syndromes, new biomarkers
 - Treatment opportunities
 - Caveats:
 - _ classification based on Ab tests and/or therapeutic response
 - _ **missed opportunities for early treatment**
- => **A worldwide experts group build sets of criteria for earlier clinical diagnosis**

Probable anti-NMDA receptor encephalitis*

Diagnosis can be made when all three of the following criteria have been met:

- 1 Rapid onset (less than 3 months) of at least four of the six following major groups of symptoms:
 - Abnormal (psychiatric) behaviour or cognitive dysfunction
 - Speech dysfunction (pressured speech, verbal reduction, mutism)
 - Seizures
 - Movement disorder, dyskinesias, or rigidity/abnormal postures
 - Decreased level of consciousness
 - Autonomic dysfunction or central hypoventilation
- 2 At least one of the following laboratory study results:
 - Abnormal EEG (focal or diffuse slow or disorganised activity, epileptic activity, or extreme delta brush)
 - CSF with pleocytosis or oligoclonal bands
- 3 Reasonable exclusion of other disorders (appendix)

Diagnosis can also be made in the presence of three of the above groups of symptoms accompanied by a systemic teratoma

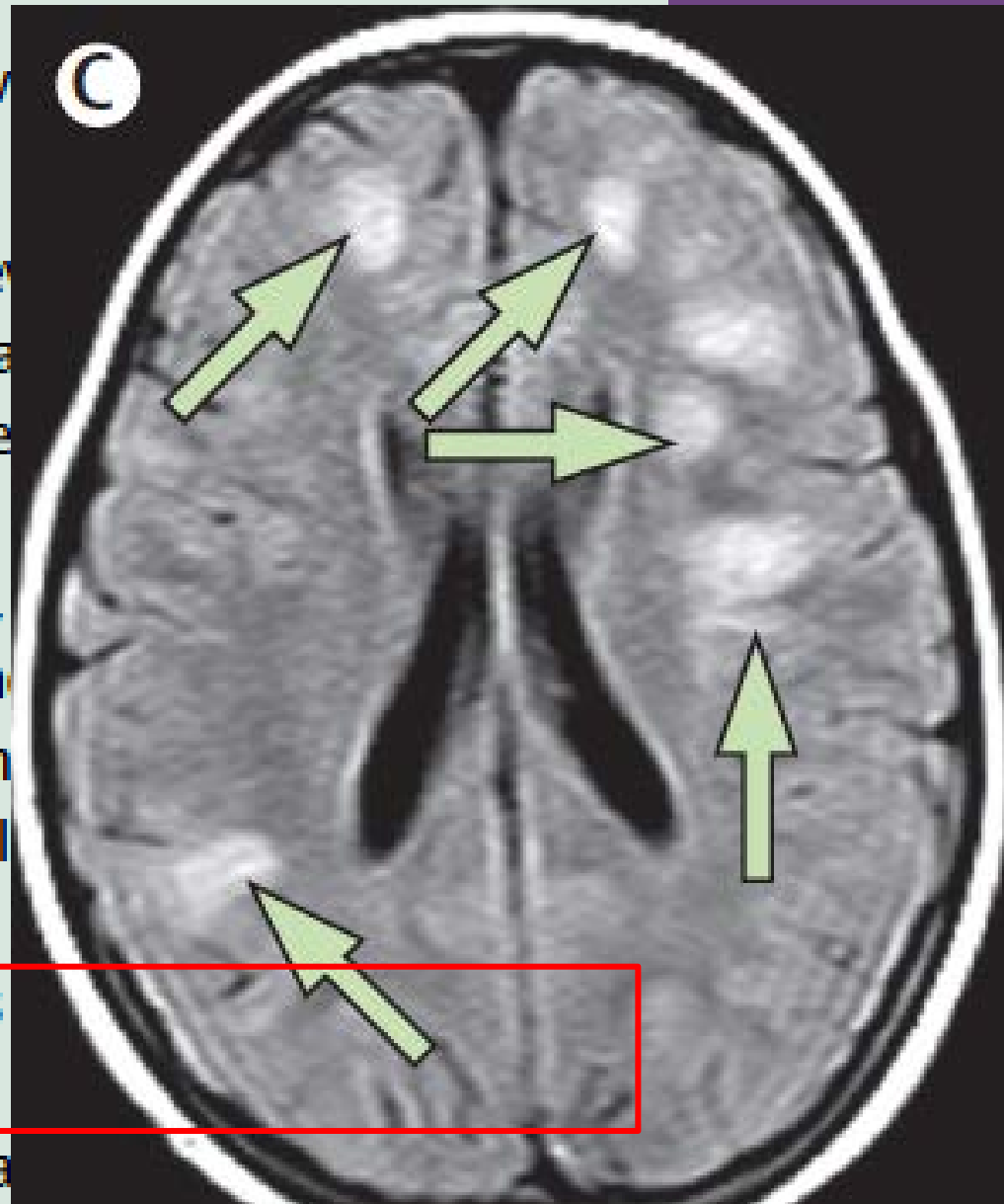
Definite anti-NMDA receptor encephalitis*

Diagnosis can be made in the presence of one or more of the six major groups of symptoms and IgG anti-GluN1 antibodies, † after reasonable exclusion of other disorders

Panel 3: Diagnostic criteria for definite acute disseminated encephalomyelitis³²

Diagnosis can be made when all five have been met:

- 1 A first multifocal, clinical CNS episode of inflammatory demyelinating character
- 2 Encephalopathy that cannot be better explained by another disorder
- 3 Abnormal brain MRI:
 - Diffuse, poorly demarcated, predominantly involving the white matter
 - T1-hypointense lesions in the white matter
 - Deep grey matter abnormalities (e.g., basal ganglia) can be present
- 4 No new clinical or MRI findings since symptom onset
- 5 Reasonable exclusion of alternative diagnoses



Panel 6: Diagnostic criteria for Hashimoto's encephalopathy

Diagnosis can be made when all six of the following criteria have been met:

- 1 Encephalopathy with seizures, myoclonus, hallucinations, or stroke-like episodes
- 2 Subclinical or mild overt thyroid disease (usually hypothyroidism)
- 3 Brain MRI normal or with non-specific abnormalities
- 4 Presence of serum thyroid (thyroid peroxidase, thyroglobulin) antibodies*
- 5 Absence of well characterised neuronal antibodies in serum and CSF
- 6 Reasonable exclusion of alternative causes

*There is no disease-specific cutoff value for these antibodies (detectable in 13% of healthy individuals).¹⁰⁰

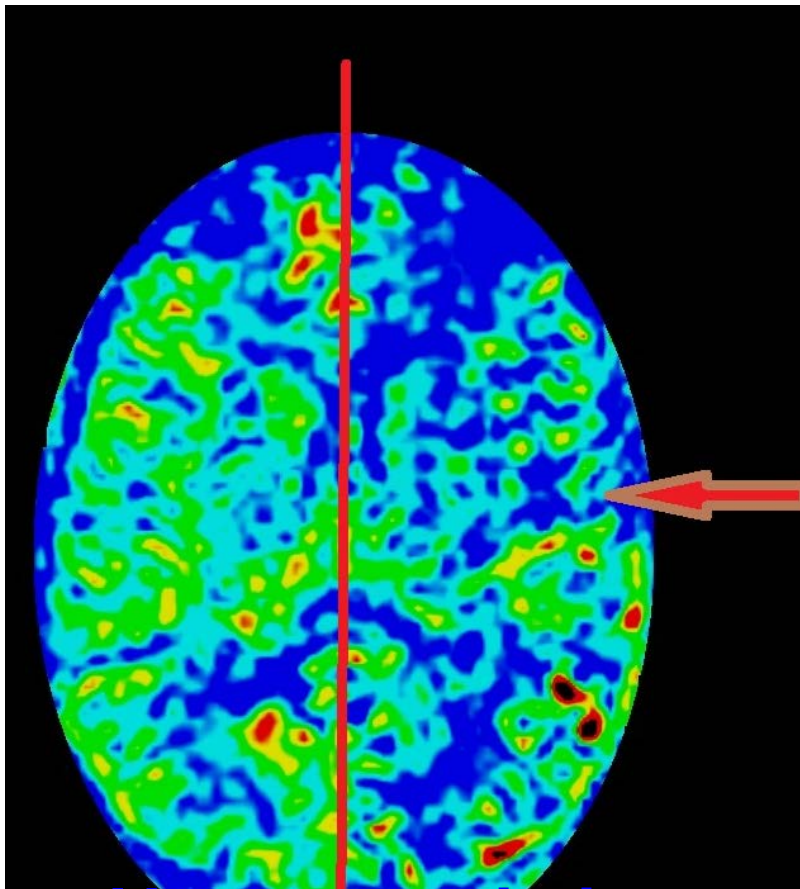
Case 2

- **34 year-old man**
- **Past medical history = migraine**
- **May 2016**
 - Motor deficit right arm+ paresthesia + speech disorders
 - Fever 38.3° C
- **Diagnostic workout**
 - Brain MRI (1 hour after symptom onset): unremarkable
 - CSF: 7 cells/mm³, 100% lymphos, prot. 1.4 g/L
- **Aciclovir IV**
 - Neurological symptoms resolved (total duration, 6 h)
 - Headache

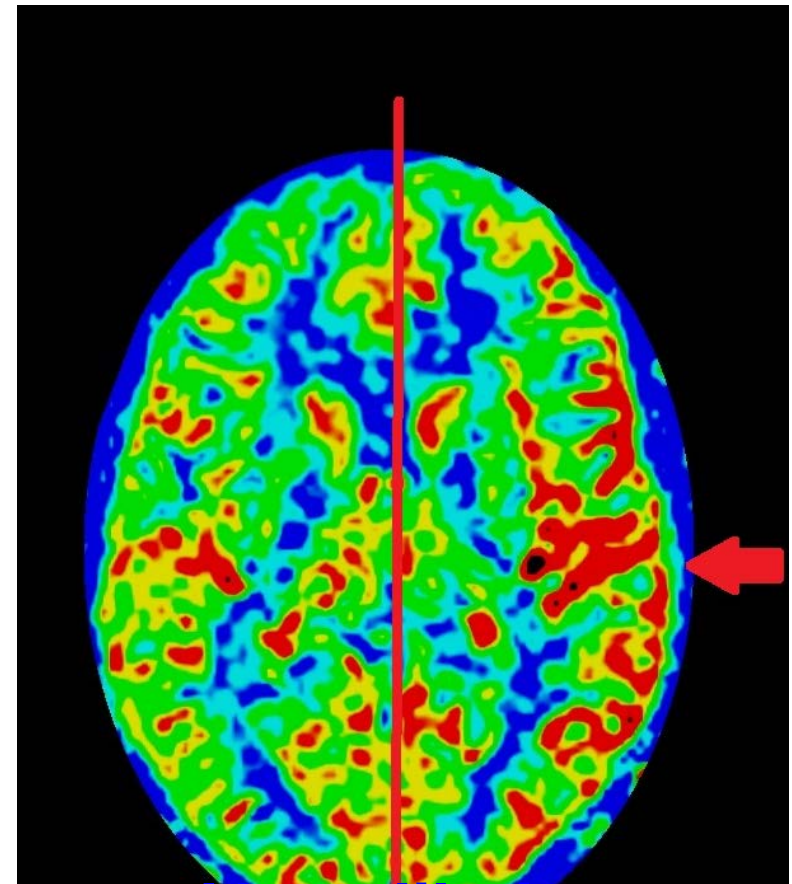
Hemiplegic migraine, or Acute confusional migraine

Arterial spin labeling (ASL) Day 0

ASL Day 2



**Vasoconstriction
(aura)**



**Vasodilation
(headache)**

Case Definitions, Diagnostic Algorithms, and Priorities in Encephalitis: Consensus Statement of the International Encephalitis Consortium

A. Venkatesan,¹ A. R. Tunkel,² K. C. Bloch,^{3,4} A. S. Luring,⁵ J. Sejvar,⁶ A. Bitnun,⁷ J-P. Stahl,⁸ A. Mailles,⁹ M. Drebot,¹⁰ C. E. Rupprecht,¹¹ J. Yoder,¹² J. R. Cope,¹² M. R. Wilson,^{13,14} R. J. Whitley,^{15,16,17,18} J. Sullivan,¹⁹ J. Granerod,²⁰ C. Jones,^{21,22} K. Eastwood,²³ K. N. Ward,^{20,24} D. N. Durrheim,^{25,26} M. V. Solbrig,²⁷ L. Guo-Dong,²⁸ and C. A. Glaser,²⁹ on behalf of the International Encephalitis Consortium

Table 1. Diagnostic Criteria for Encephalitis and Encephalopathy of Presumed Infectious or Autoimmune Etiology

Major Criterion (required):

Patients presenting to medical attention with altered mental status (defined as decreased or altered level of consciousness, lethargy or personality change) lasting ≥ 24 h with no alternative cause identified.

Minor Criteria (2 required for possible encephalitis; ≥ 3 required for probable or confirmed^a encephalitis):

Documented fever $\geq 38^{\circ}$ C (100.4° F) within the 72 h before or after presentation^b

Generalized or partial seizures not fully attributable to a preexisting seizure disorder^c

New onset of focal neurologic findings

CSF WBC count ≥ 5 /cubic mm^d

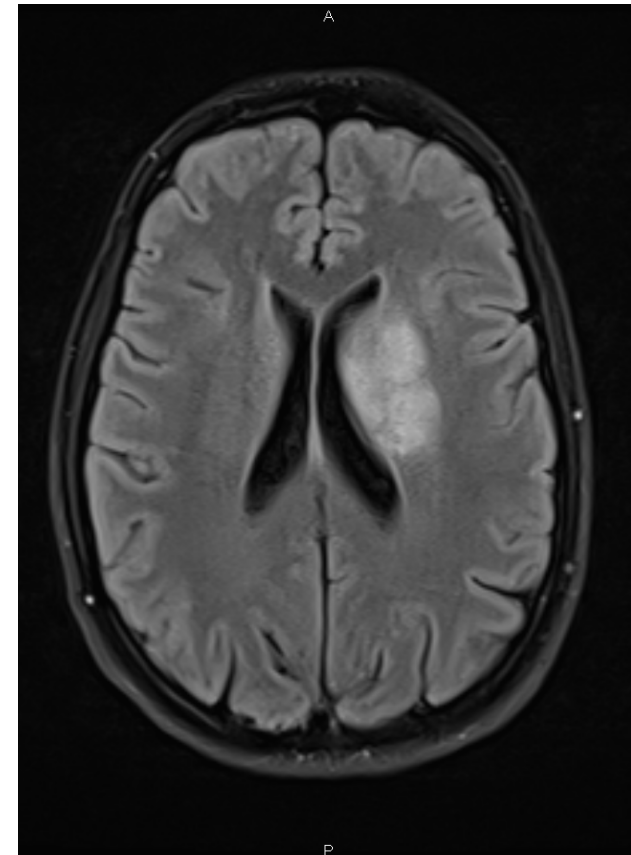
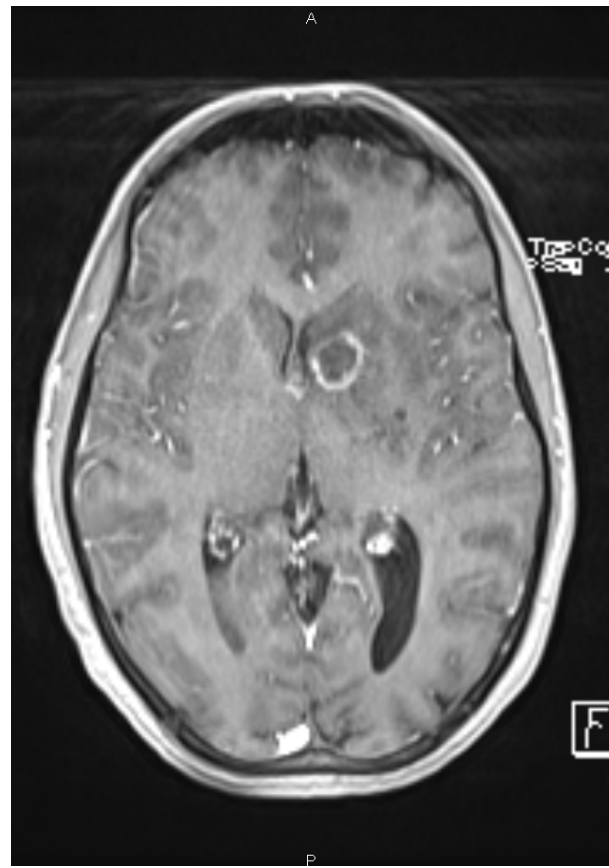
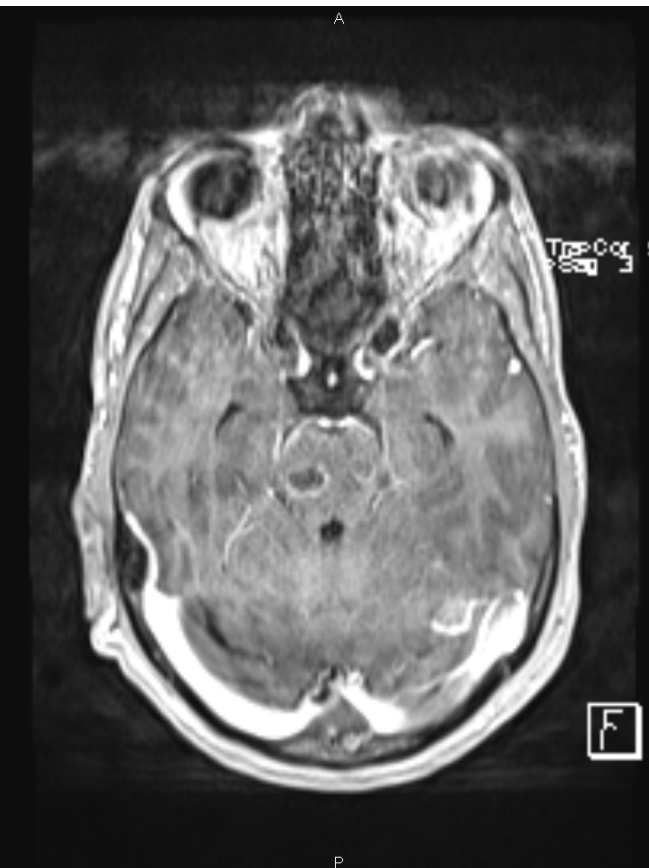
Abnormality of brain parenchyma on neuroimaging suggestive of encephalitis that is either new from prior studies or appears acute in onset^e

Abnormality on electroencephalography that is consistent with encephalitis and not attributable to another cause.^f

Case 3

- **33 year-old man**
- **Past medical history = IVDU (still active)**
- **November 2015**
 - 10-day history of headache
 - Fever (38° C)
 - Speech disorders
 - Right facial palsy

18 Nov. 2015



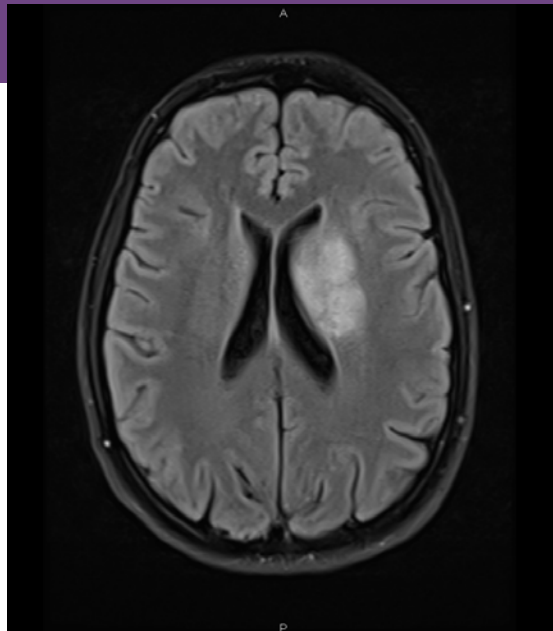
Case 3

- **Blood cultures sterile**
- **Echocardiography unremarkable**
- **Neurosurgeons & patient decline stereotactic biopsy**

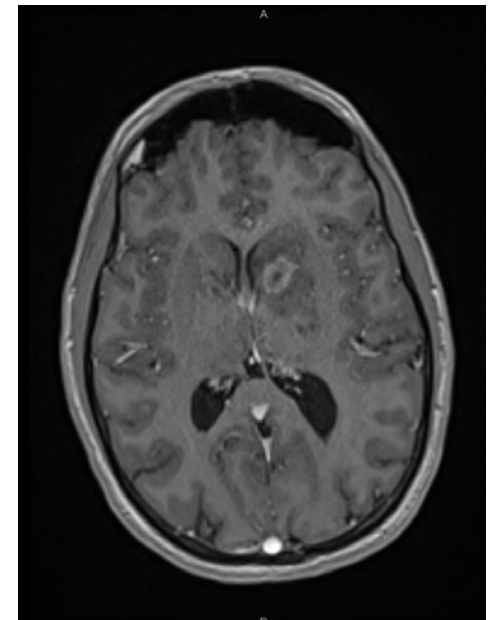
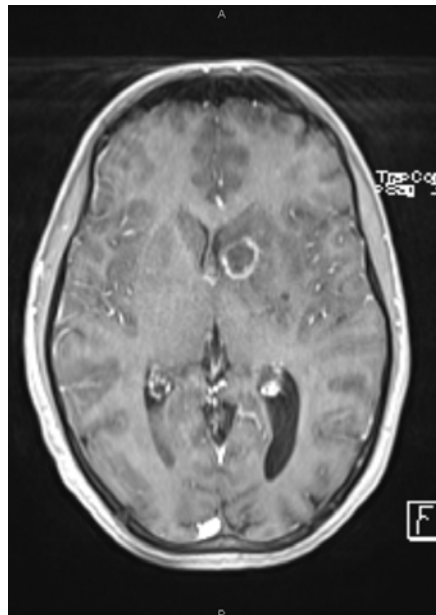
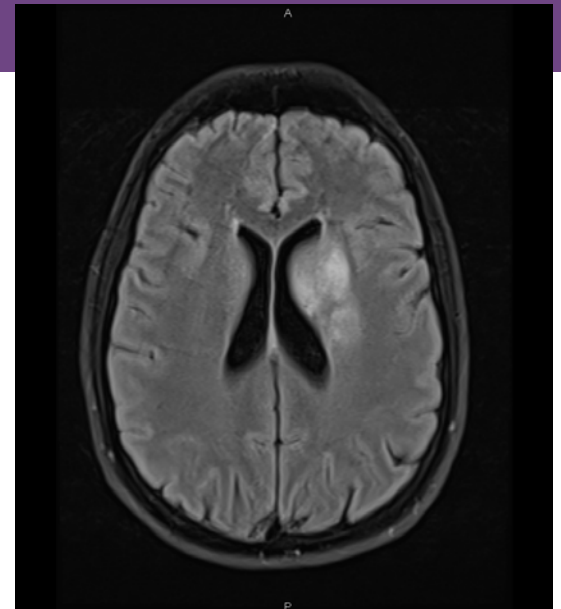
⇒ **ceftriaxone/metronidazole, 6-12 weeks**

⇒ **+ monitoring (clinical, imaging)**

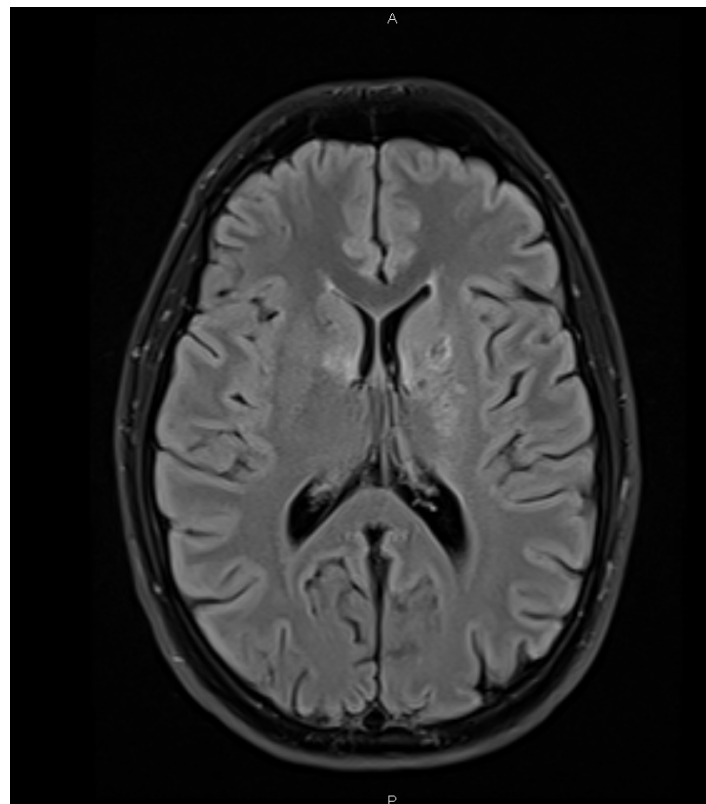
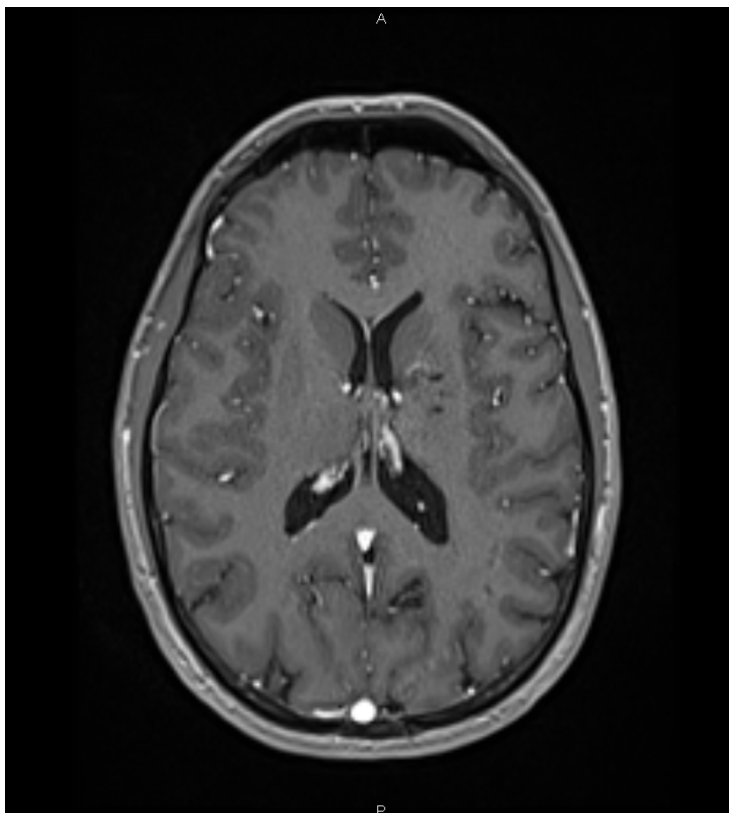
18 Nov. 2015



7 Dec. 2015

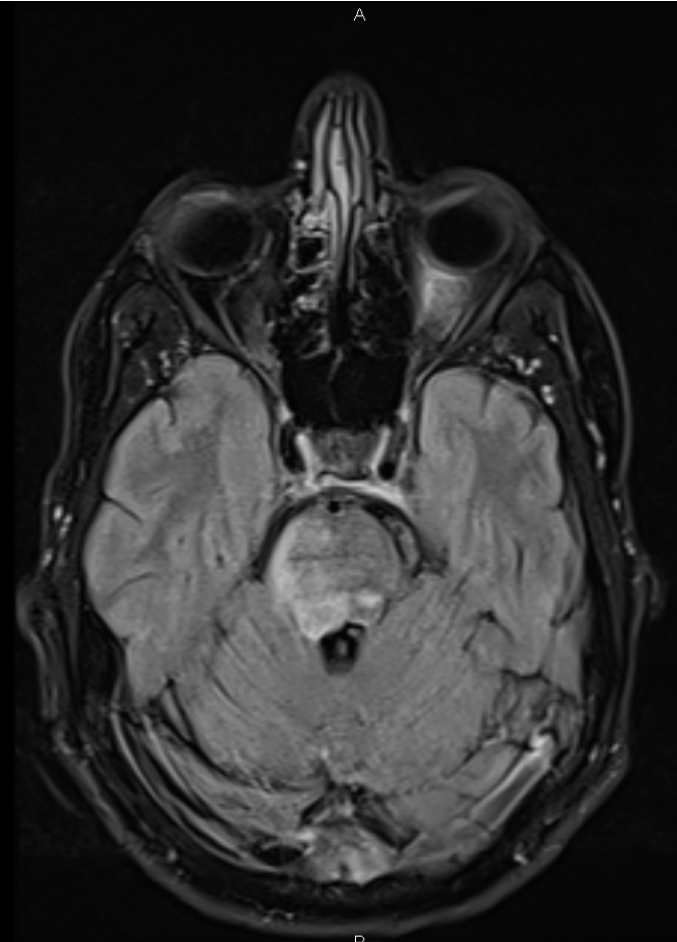
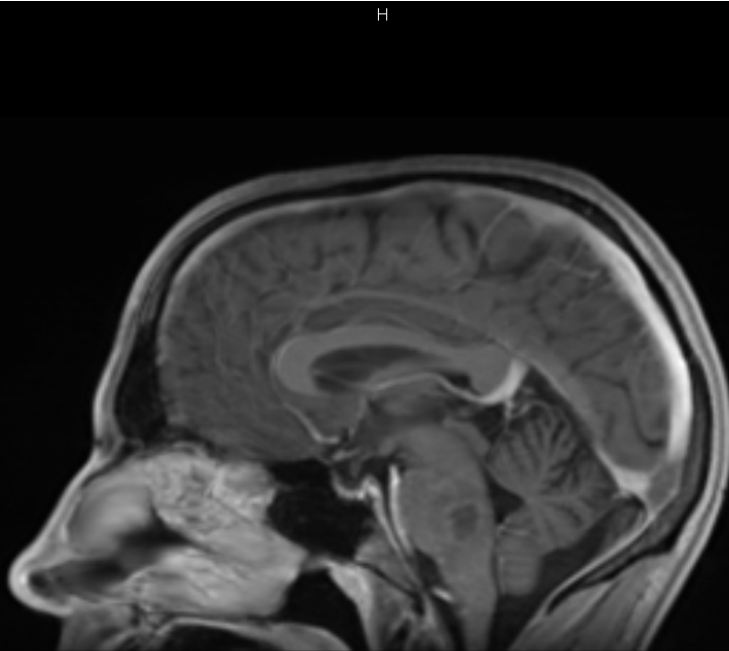


Feb. 2016



March 2016

- Clinical relapse: Left hemiplegia / Right facial palsy



- **Clinical relapse: Left hemiplegia / Right facial palsy**
- **Stereotactic biopsy**
 - Brownish fluid
 - Mostly neutrophils
 - No pathogen (including broad spectrum PCR for fungi, bacteria, parasites)
- **Medical history reinvestigated**
 - Recurring aphtous ulcers (mouth)
 - Genital ulcers
 - ⇒ Patient transferred to the reference center for Behcet disease
 - ⇒ Diagnosis confirmed, immunosuppressive treatment effective

Case 4. Complicated cholecystectomy

A previously healthy, 67-year-old man

- Elective cholecystectomy for cholelithiasis on June, 15th
- June 17th: T = 38.5° C, confusion, nuchal rigidity
- Contrast-enhanced brain CT scan normal

CSF

- 150 white cells/mm³ (75% neutrophils)
- Protein, 2 g/L Glucose normal
- Gram stain negative

Bacteriology negative (including PCR)

Case 4. Complicated cholecystectomy

iv amoxicillin, 12 g/day + aciclovir, 10 mg/kg x 3

June 20th: worse (T = 39° C) – altered consciousness

- **Contrast-enhanced Brain MRI normal**
- **Redo CSF – not clear anymore**
 - **500 white cells/mm³, 75% neutrophils**
 - **Protein, 3 g/L - Glucose, 2 mmol/L (glycemia, 4.5 mmol/L)**

Patient intubated => to the ICU / T = 40° C on day 5

Microbiology tests all negative

The wife wants to see you !

Case 4. Complicated cholecystectomy

Patient was fine until he arrived in the hospital

Last year, he had a strange disease

- Pharyngitis => Amoxicillin, 1 g x 2/day (oral)
- After a few days,
 - Headache, Fever
 - ‘strange behaviour’
- GP suggested that it may be drug-related, amoxicillin discontinued
- Returned to his normal state within a few hours

NB: amoxicillin part of perioperative prophylaxis for gallbladder surgery

⇒ Amoxicillin discontin'd, patient improved in 24 h

Drug-Induced Aseptic Meningitis

Over 200 cases reported in the literature

- Delay 2-7 days post introduction
- No dose-effect
- Acute neutrophilic meningitis
- Encephalitis signs not rare (30%)
- No diagnostic test
 - Rely on past medical history
 - Exclude other causes
 - ‘Accidental’ re-introduction
- Improves fast once treatment discontinued

Moris G et al. JAMA intern med 2014

Drug-Induced Aseptic Meningitis

Table 1. Drugs Involved in Drug-Induced Aseptic Meningitis (DIAM)^a

Drugs Involved (No. of Cases)	Female Sex, %	Age, Mean (SD) [range], y	Range of Latency (Median)	Prior Exposure to Drug, %
NSAIDs (n = 72 cases): Ibuprofen (46), sulindac (7), naproxen sodium (7), tolmetin (1), diclofenac sodium (2), ketoprofen (1), celecoxib (1), dexibuprofen (1), piroxicam (1), ketorolac (1), rofecoxib (4)	62	39 (15) [21-73]	30 min-4 mo (8 h)	35
Antibiotics (n = 69 cases): Trimethoprim-sulfamethoxazole (32), trimethoprim (11), amoxicillin (8), ^b sulfamethoxazole (1), isoniazid (1), ciprofloxacin (2), penicillin (1), metronidazole (3), cephalosporin (2), pyrazinamide (1), sulfisoxazole (1), fumagillin (1), minocycline (1), ornidazole (1), rifampicin (1), valacyclovir (2)	59	46 (23) [1-90]	10 min-3 mo (6 h)	33
IS-IM agents (n = 19 cases): Cetuximab (5), efalizumab (2), infliximab (4), adalimumab (1), leflunomide (1), methotrexate (1), salazopyrin (1), sulfasalazine (3), etanercept (1)	53	51 (11) [31-78]	3 h-5 mo (48 h)	26
Antiepileptic drugs ^c (n = 34 cases): Lamotrigine (30), carbamazepine (4)	82	33 [15-79]	1-42 d (14)	NA

Moris G et al. JAMA intern med 2014

Drug-Induced Aseptic Meningitis

Table 2. Percentages of Clinical Signs and Symptoms of Drug-Induced Aseptic Meningitis

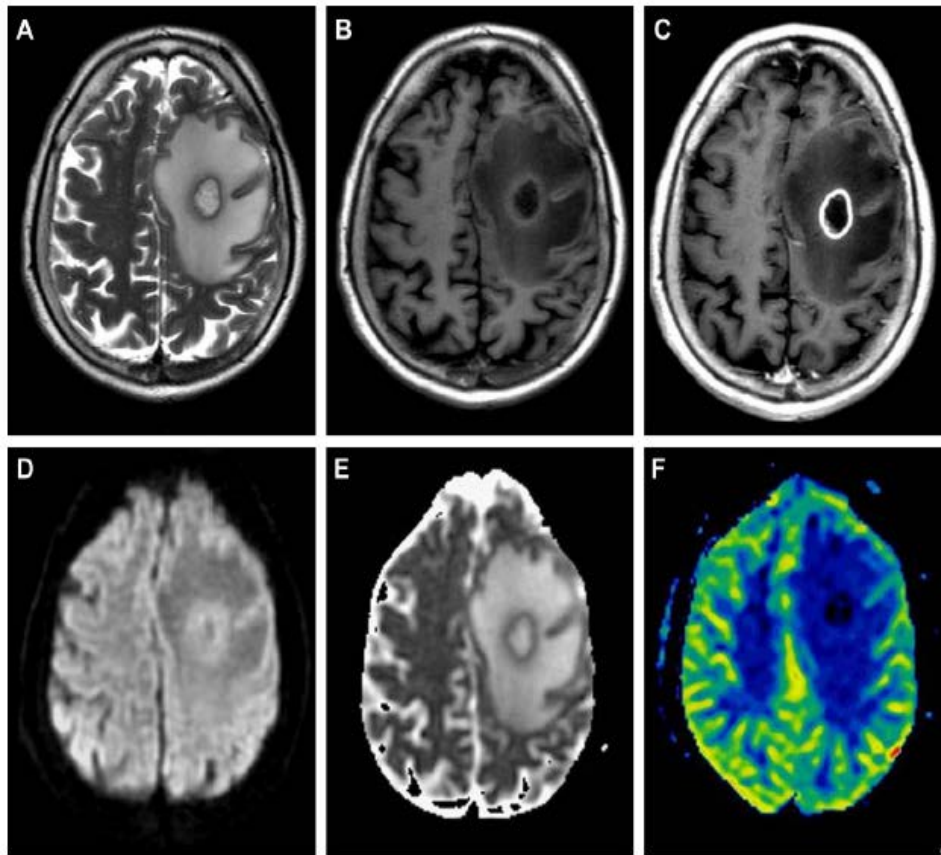
Sign or Symptom	NSAIDs	ATB	IS-IM	SLE	Total
Fever	91	88	72	88	88
Headache	81	84	83	83	82
Meningeal signs	73	71	67	75	72
Nausea and vomiting	60	49	11	67	49
Rash	16	11	11	30	13
Abdominal pain	6	6	6	17	5
Arthromyalgias	16	13	17	25	15
Hypotension	15	3	6	29	9
Facial edema	16	16	6	17	14
Abnormal consciousness ^a	49	55	11	58	47
Focal neurologic deficit	10	7	NA	9	10
Seizures	4	7	NA	9	5

Moris G et al. JAMA intern med 2014

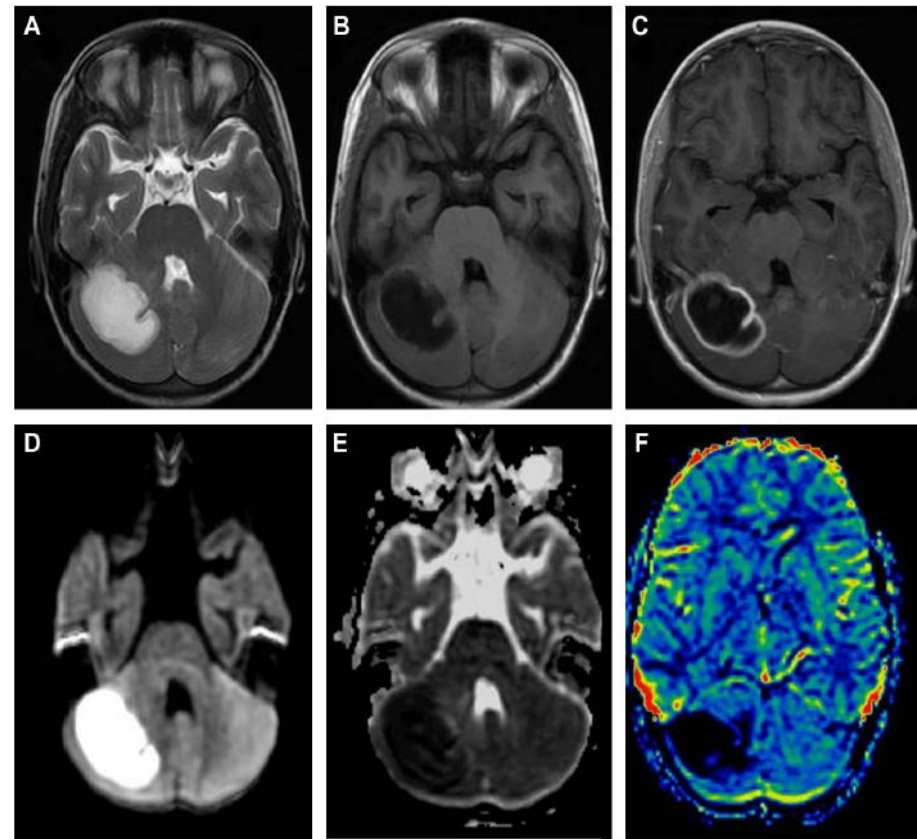
Other encephalitis mimickers usually resolved with high quality imaging

- Cerebral thrombosis
- Brain abscess
- Empyema
- Malignancies
 - Lymphoma
 - Glioma

Diffusion Weighted Imaging (DWI) Apparent Diffusion Coefficient (ADC)

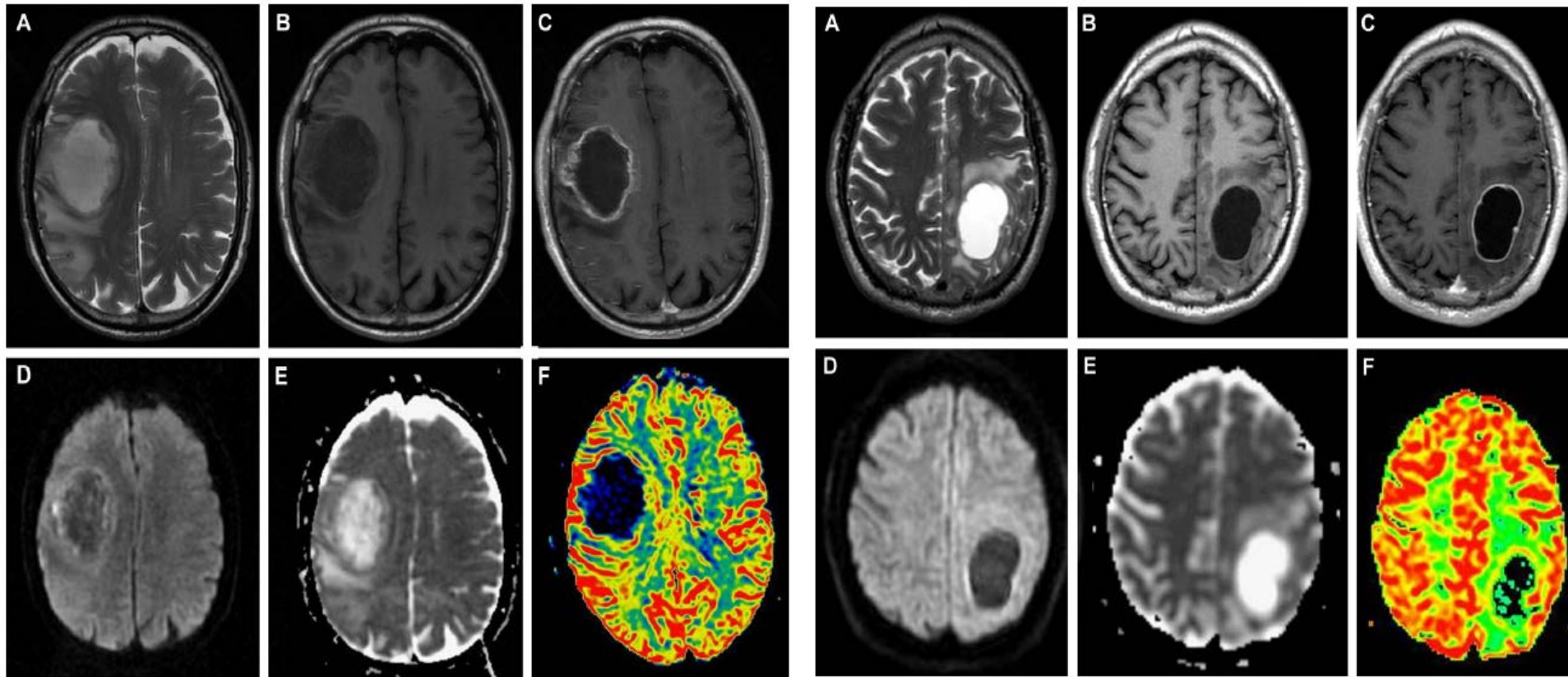


High ADC =>
non-pyogenic abscess



Low ADC =>
Pyogenic abscess

DWI & ADC for differential diagnosis (malignancies)



Glioblastoma

Metastasis (cancer)

Conclusions: infectious encephalitis mimickers

- Complex & evolving
- Not a rare occurrence in the field (50% of all encephalitis ?)
- Two big players
 - Auto-immune encephalitis
 - Drug-induced aseptic meningitis
- **If you don't want to fail**
 - Be 'multidisciplinary' (neurologist + ID + internist + modern biologist + brain imaging specialist)
 - Follow the progress (quite fast) and/or ask specialists

This field is moving fast, finally !

Thank you for your attention !