



JNI 15^{es} Journées
Nationales
d'Infectiologie

Bordeaux
et l'interrégion Aquitaine § Limousin



du mercredi 11 au vendredi 13 juin 2014
Palais des Congrès de Bordeaux

Session ABCES SNC Imagerie

-

Vincent Dousset MD, PhD
Université de Bordeaux / CHU de Bordeaux

1	Protocole d'Imagerie – TDM - IRM
2	Caractéristiques d'imagerie de l'Abcès Cérébral
3	Diagnostic différentiel Abcès / Tumeur Néoplasique
4	Toxoplasmose
5	Miliaires Cérébrales
6	Empyèmes Sous-Duraux
7	Cas par Cas
8	Non ce n'est pas un Abcès !

1 **Protocole d'Imagerie** – TDM - IRM

IRM 3T et 1.5T

T1 3D Pré-contraste

FLAIR 3D

Diffusion (4 mm 6 directions b 1000) 2D Trans

T2* or SWI 2D Trans

T1 3D Gadolinium

IRM 1.5T Standard

T1 Sag \pm Trans 2D Pré-contraste

FLAIR 2D Trans

Diffusion (5 mmm 6 directions b 1000) 2D Trans

T2* or SWI 2D Trans

T1 Gadolinium Trans 2D

\pm thin contiguous slices trough the skull base if cranial nerve symptoms

1 **Protocole d'Imagerie** – TDM - IRM

Séquences Additionnelles IRM 3T et 1.5T

± Venogram-MRI (or Veno-CT) pour les Thromboses Veineuses

± Angio-MRI pour les Vascularites

± Spectroscopy pour rechercher des Acides Aminés (Leu, Ala)

Moelle Epinière 3T and 1.5T

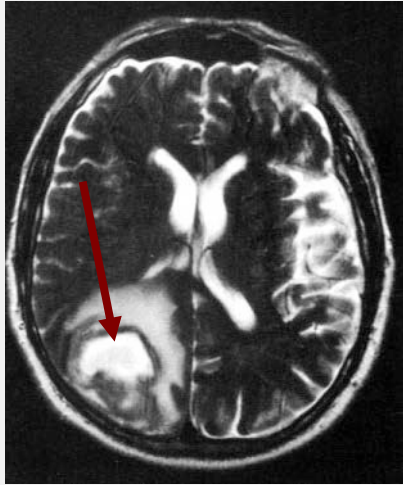
T2 Sagittal 3 mm

T1 Gadolinium Sagittal 3 mm

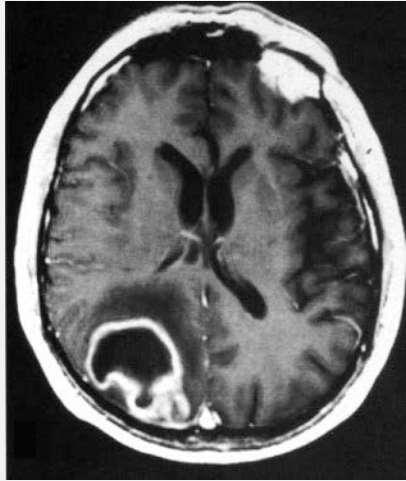
± T2 Transverse 2D

± T1 Gadolinium Transverse 2D

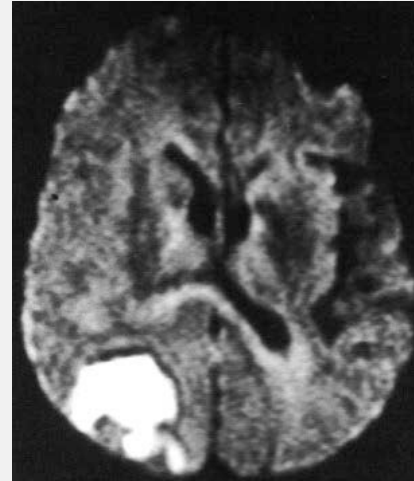
2 Caractéristiques d'imagerie de l'Abcès Cérébral



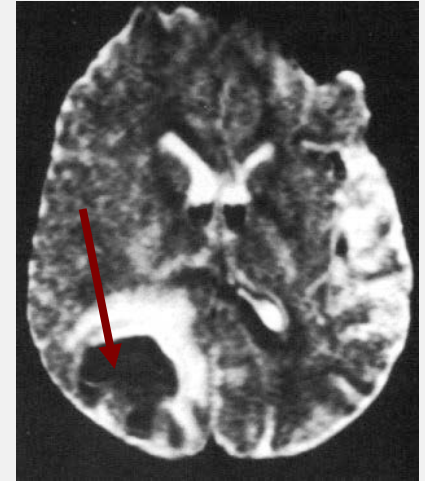
T2/FLAIR



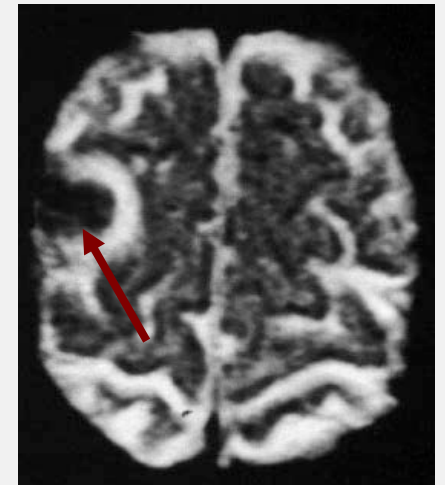
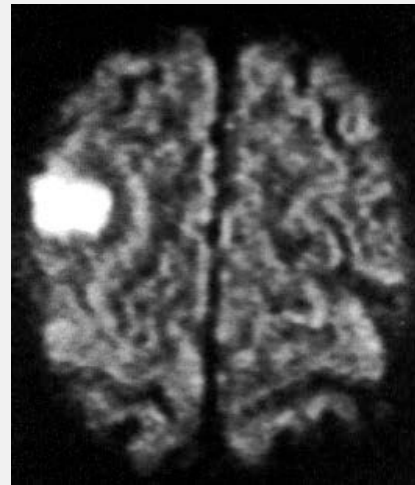
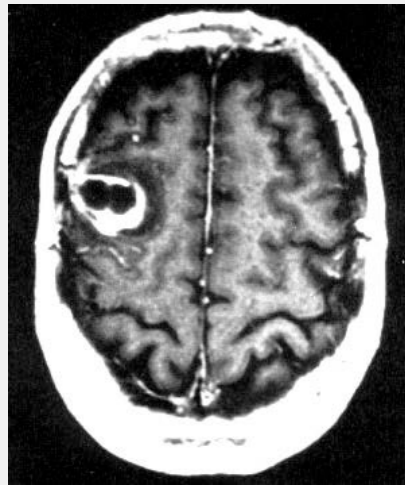
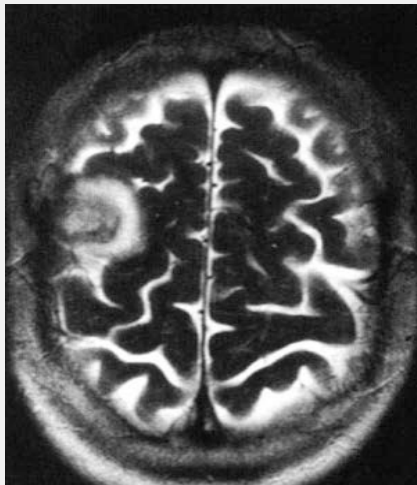
Gado



Diffusion



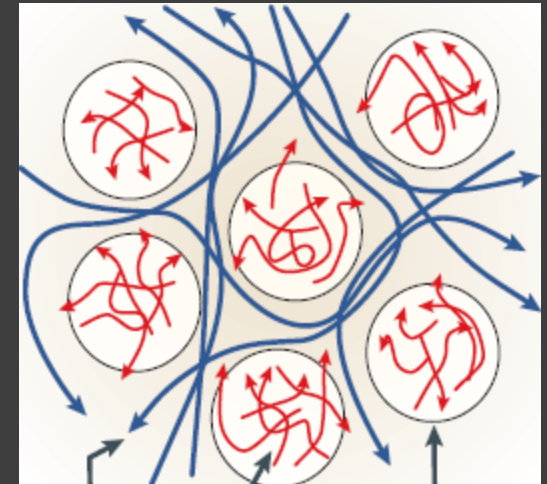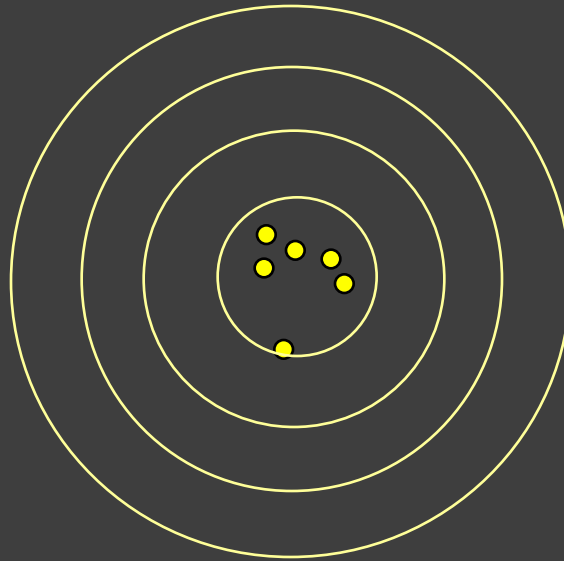
ADC

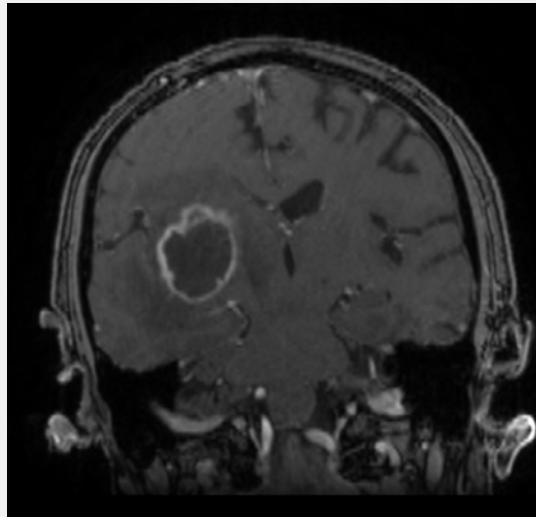


Qu'est ce que la diffusion ?

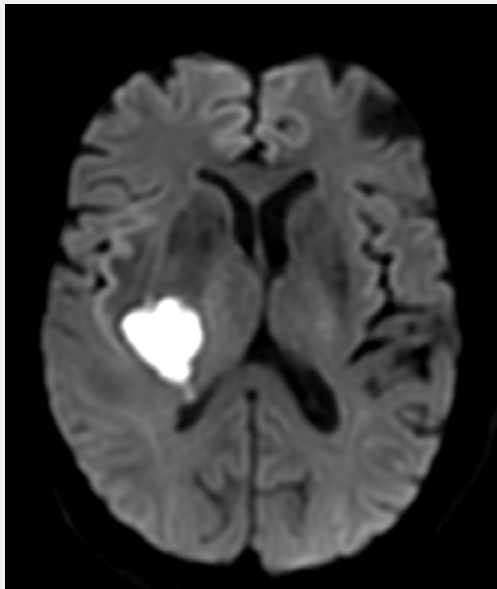


- Etude des déplacements des molécules d'eau

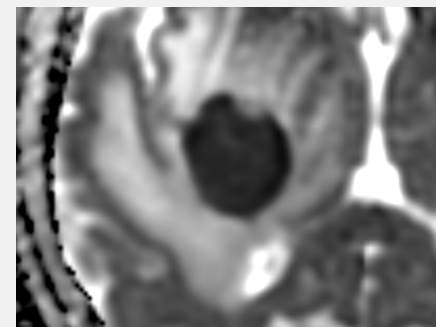




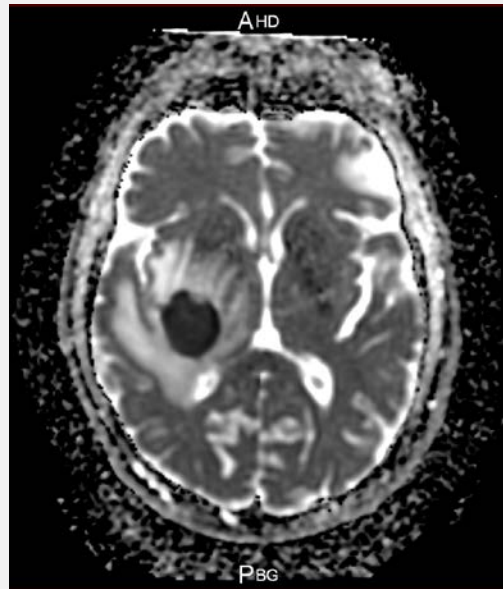
Gadolinium



Restriction de Diffusion



Diffusion

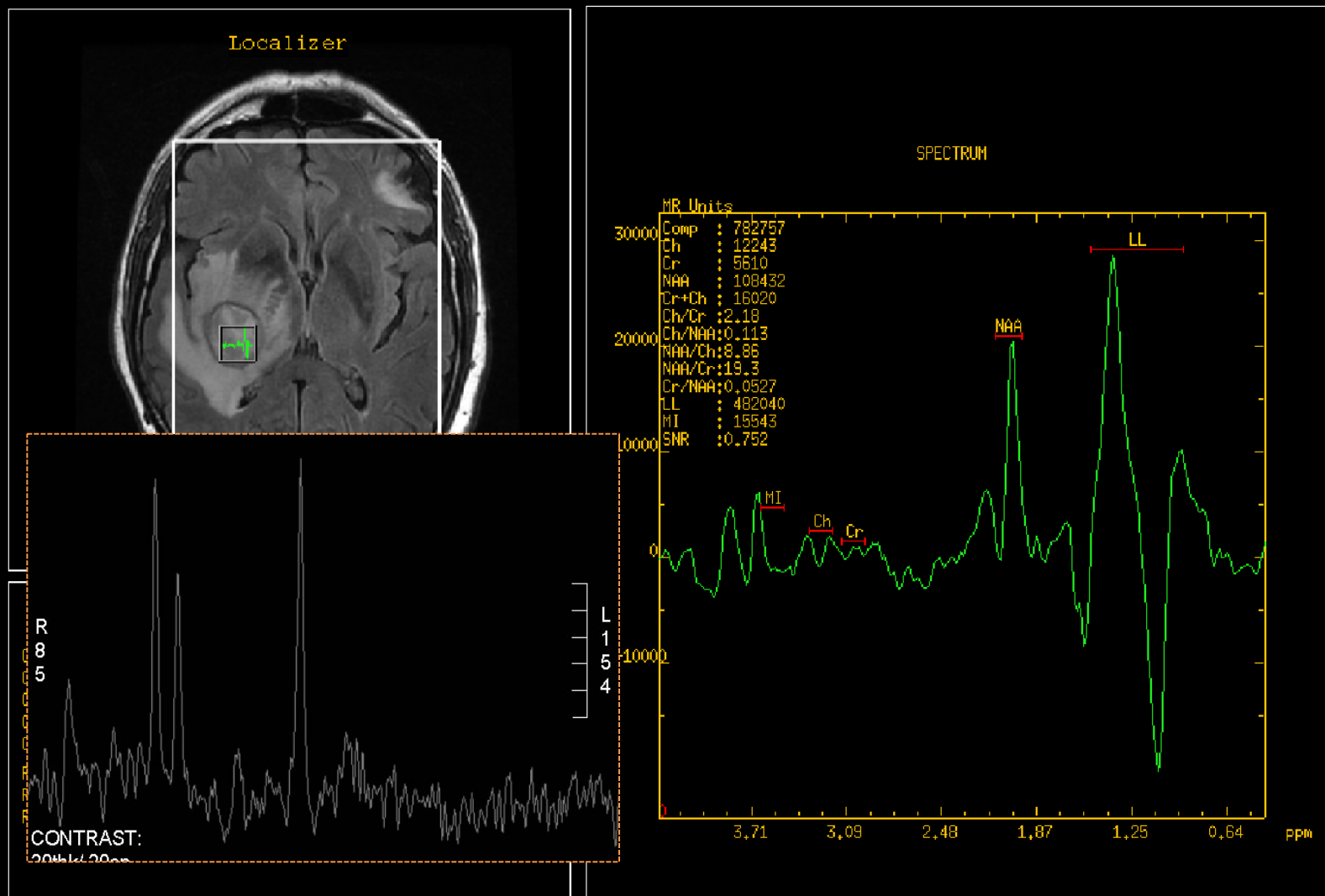


ADC

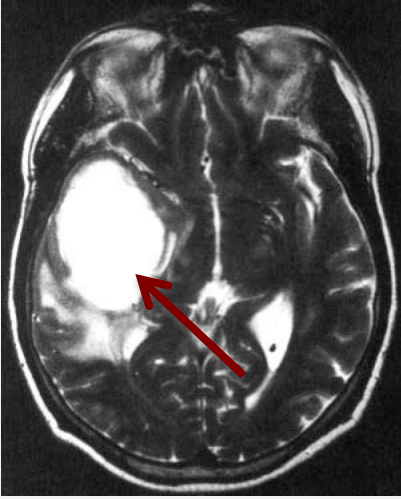
2 Caractéristiques d'imagerie de l'Abcès Cérébral

RUNOT PHILIPPE,
29/11/2013

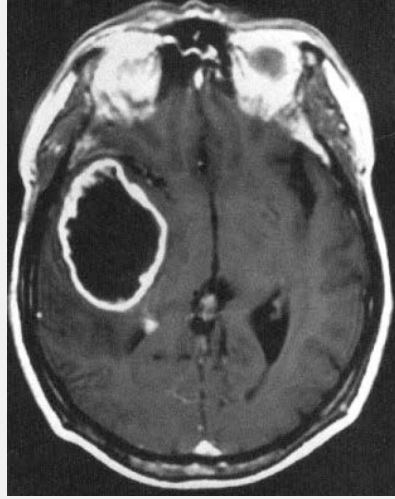
SCREENSAVE



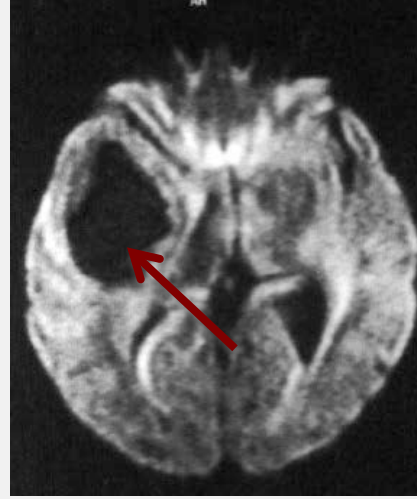
Acides-Aminés : Leucine - Alanine



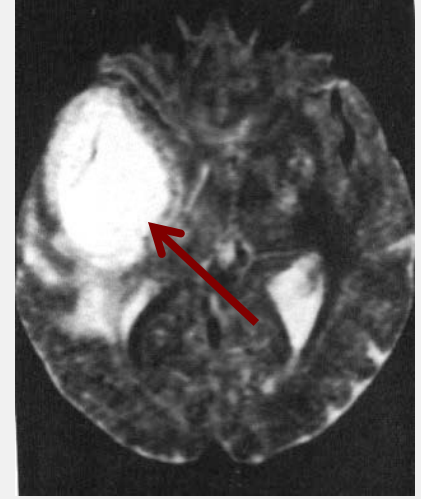
T2/FLAIR



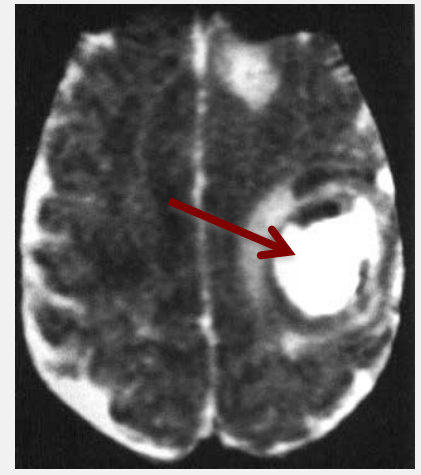
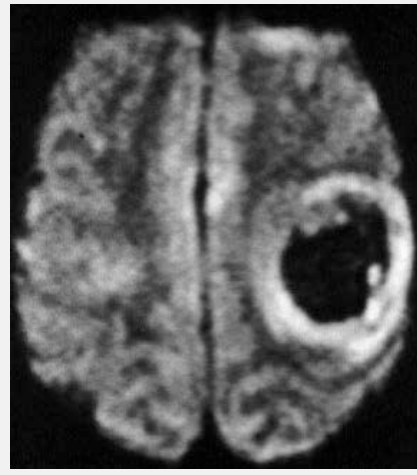
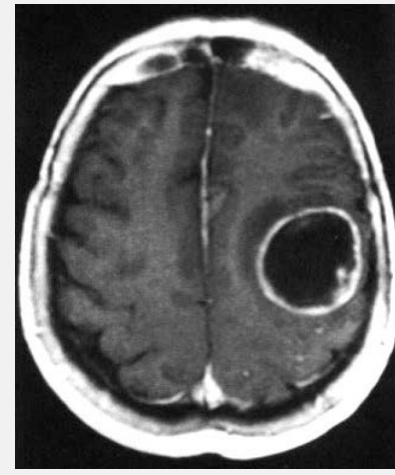
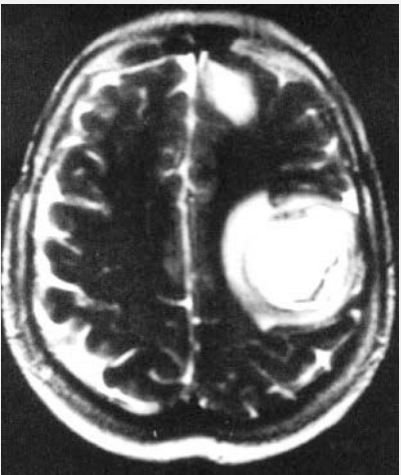
Gado

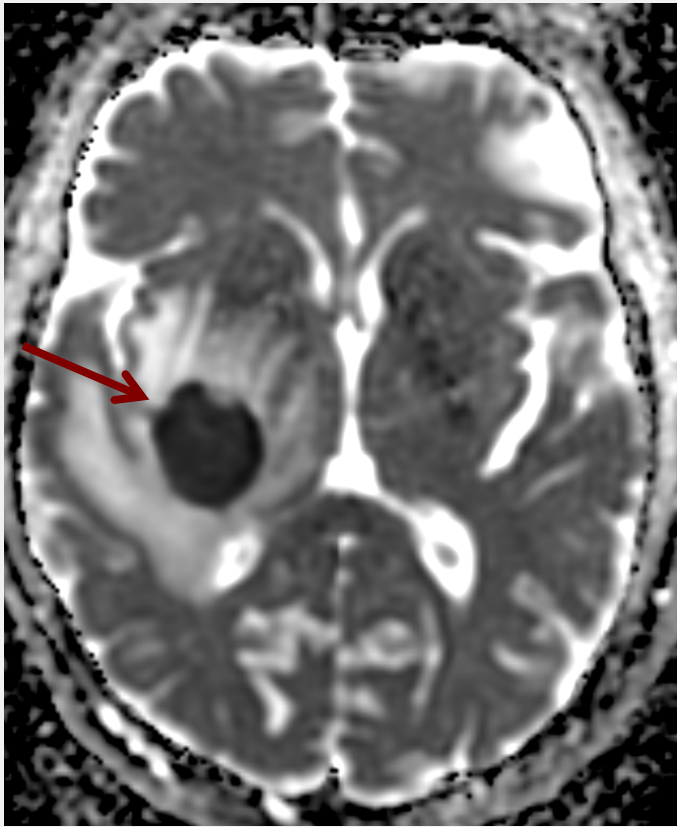


Diffusion

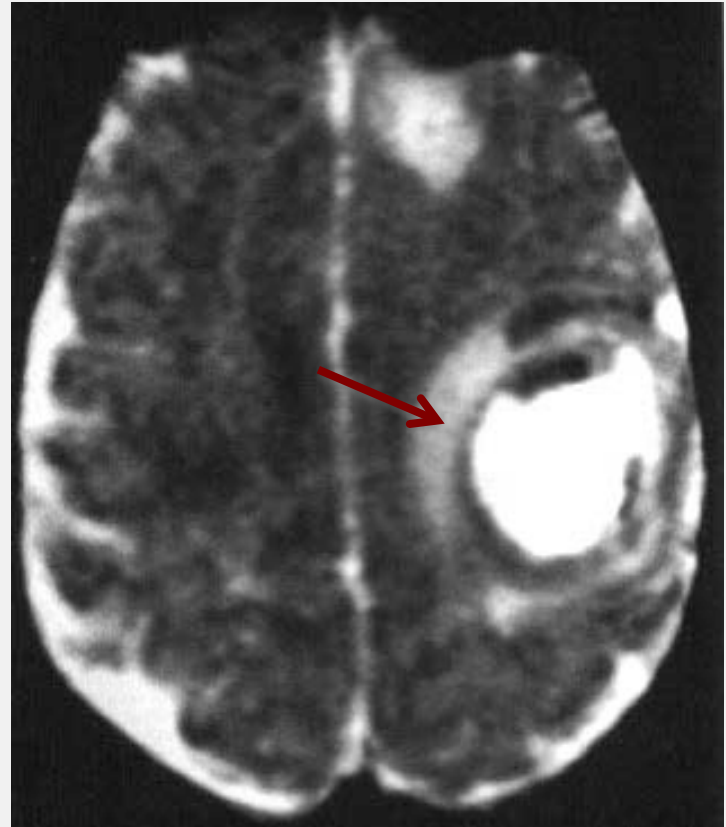

ADC



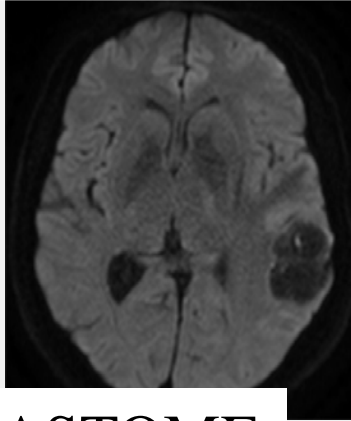
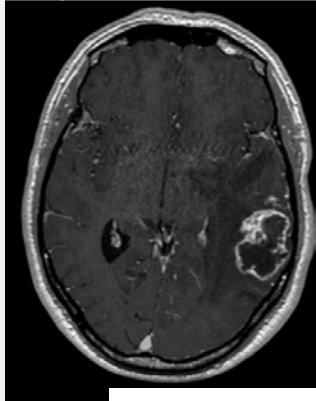


ADC

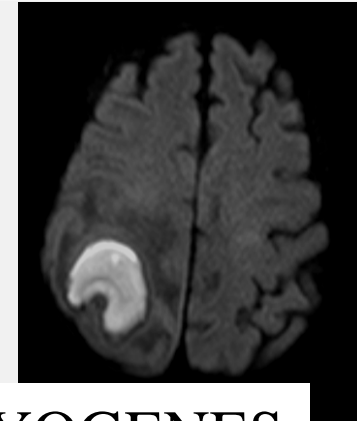
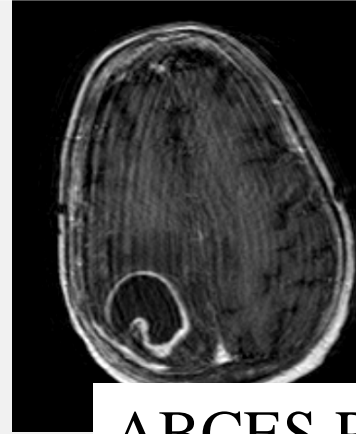


ADC

3 Diagnostic différentiel Abscès / Tumeur Néoplasique



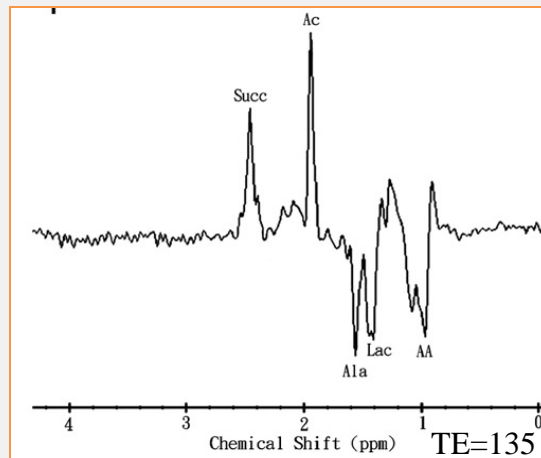
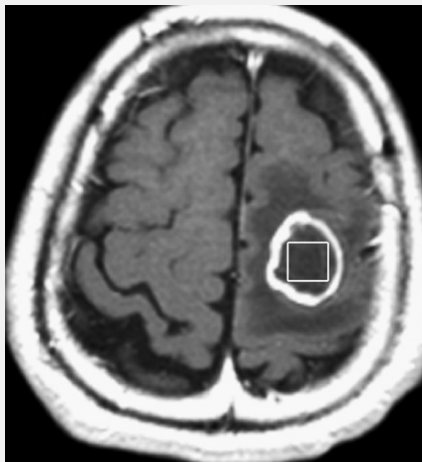
GLIOBLASTOME



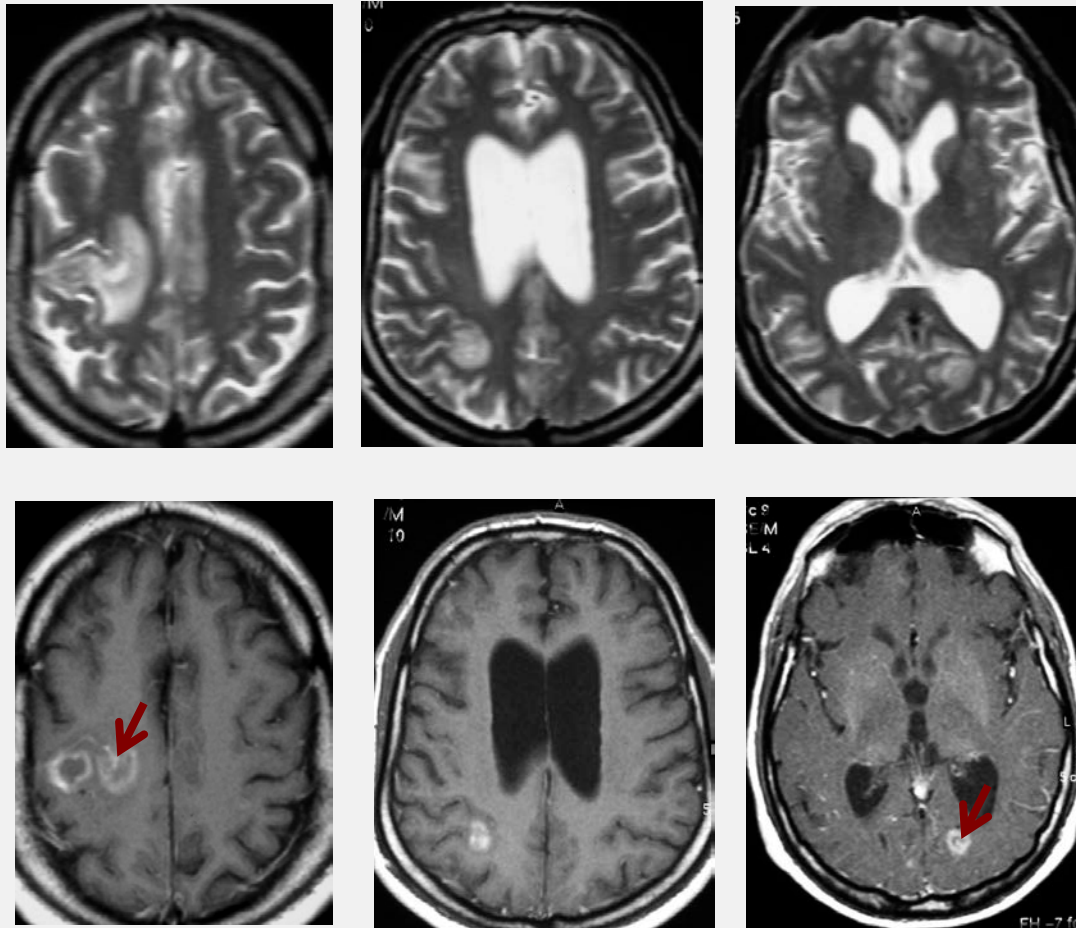
ABCES PYOGENES

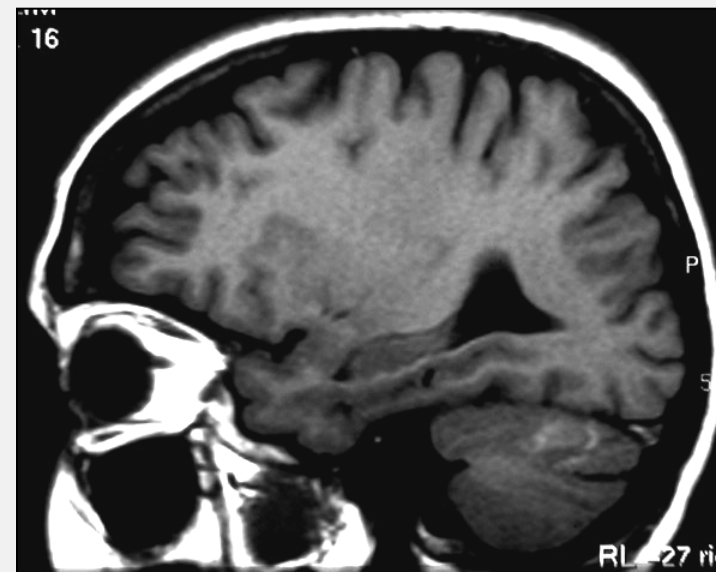
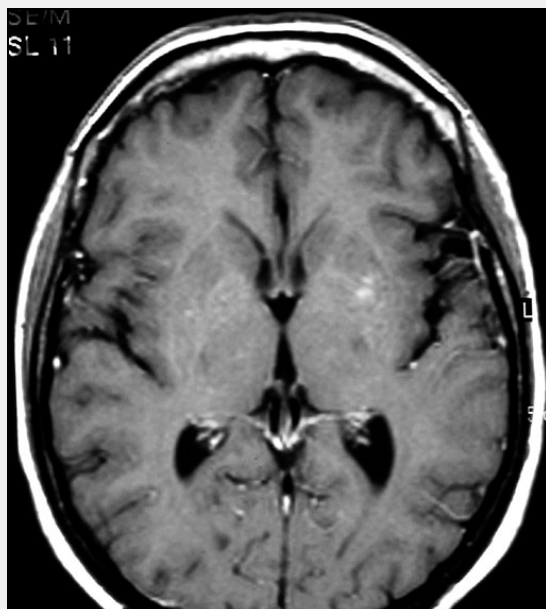
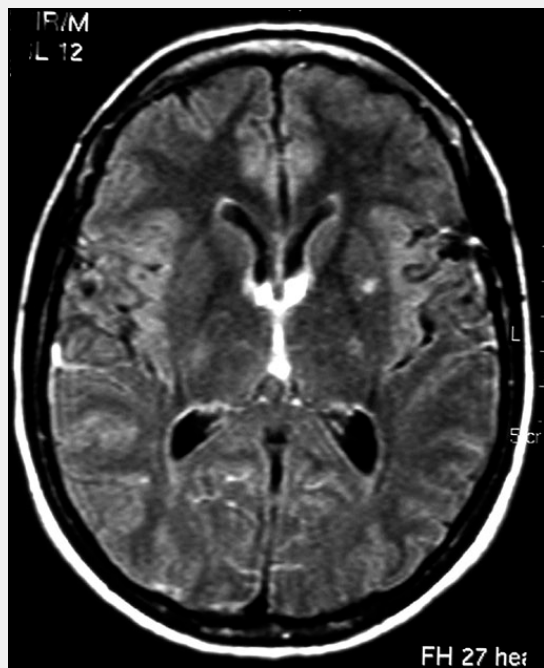
Modality	Accuracy (%)	Sensitivity (%)	Specificity (%)	PPV (%)	NPV (%)
Conventional MRI	61.4 (45.2-75.6)	61.9 (38.4-81.9)	60.9 (38.5-80.3)	59.1 (36.4-79.3)	63.6 (40.7-82.8)
DWI	95.5 (85.1-99.4)	95.2 (76.2-99.9)	95.7 (78.1-99.9)	95.2 (76.2-99.9)	95.7 (78.1-99.9)
MRS	93.2 (81.4-98.6)	85.7 (63.7-97)	100 (85.2-100)	100 (81.5-100)	88.5 (69.8-97.6)
DWI + MRS	97.7 (88.3-99.9)	95.2 (76.2-99.9)	100 (85.2-100)	100 (83.2-100)	95.8 (78.9-99.9)

Data in parentheses are 95% CIs.

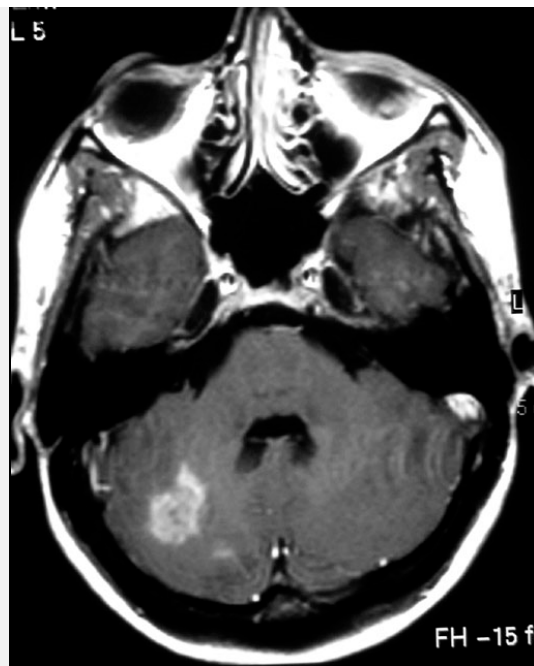
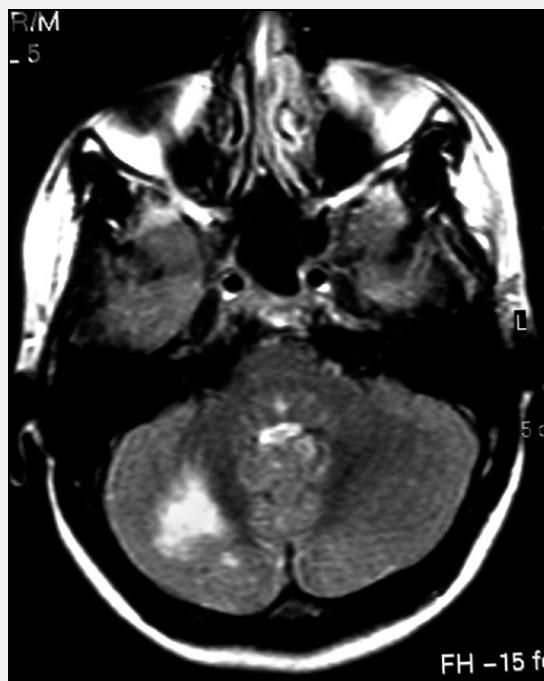

Diagnostic le plus probable chez un patient séro-positif HIV
avec des symptômes neurologiques

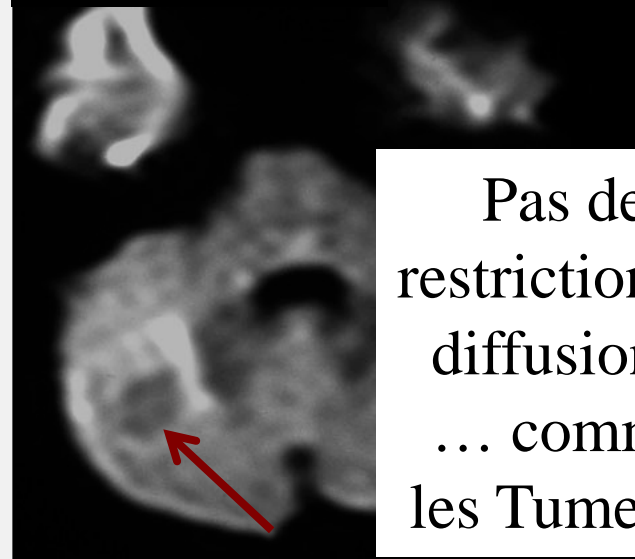




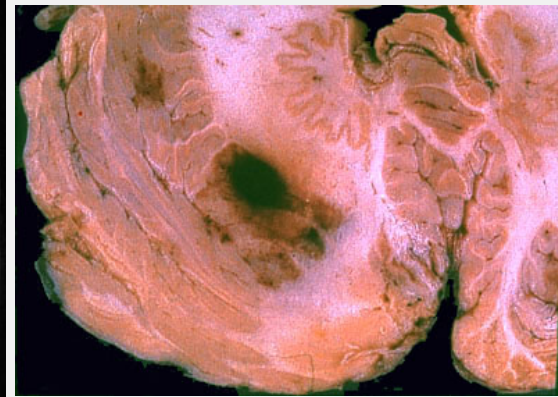
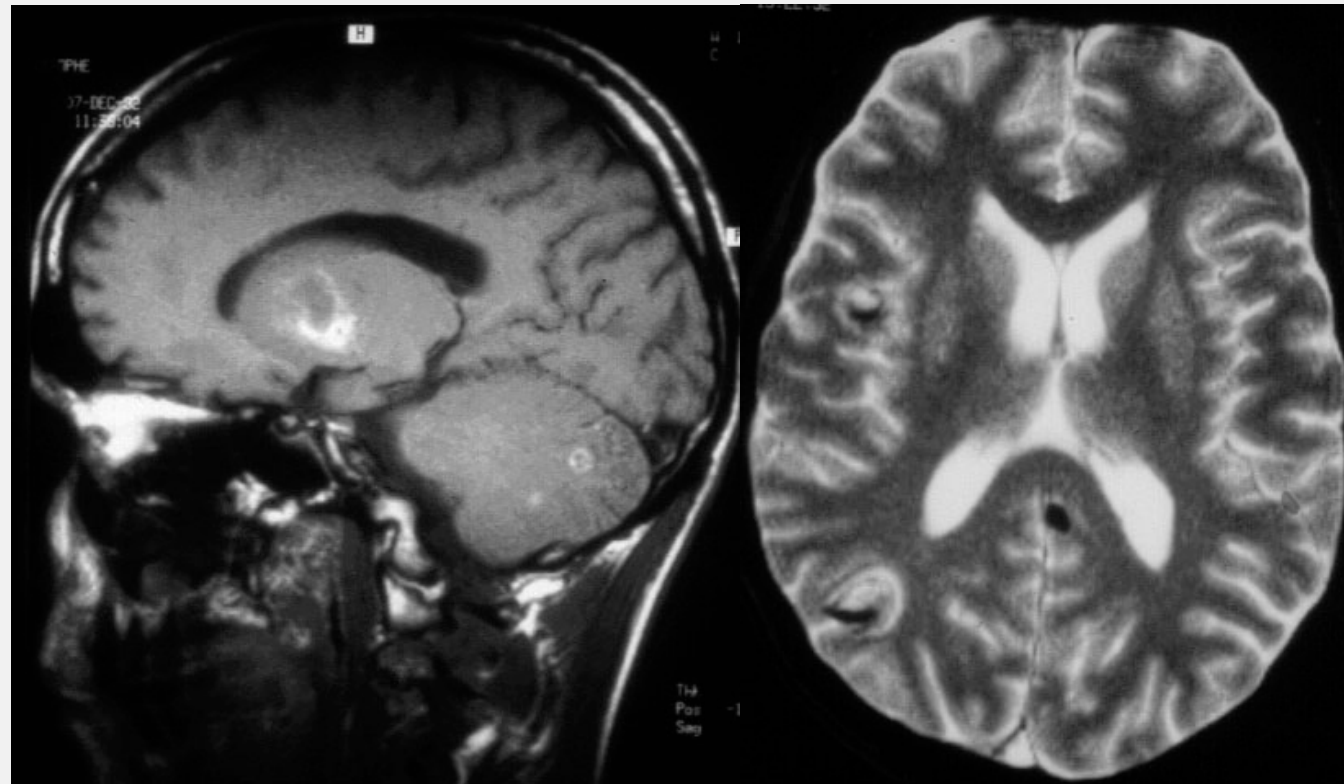
TOXOPLASMOSIS



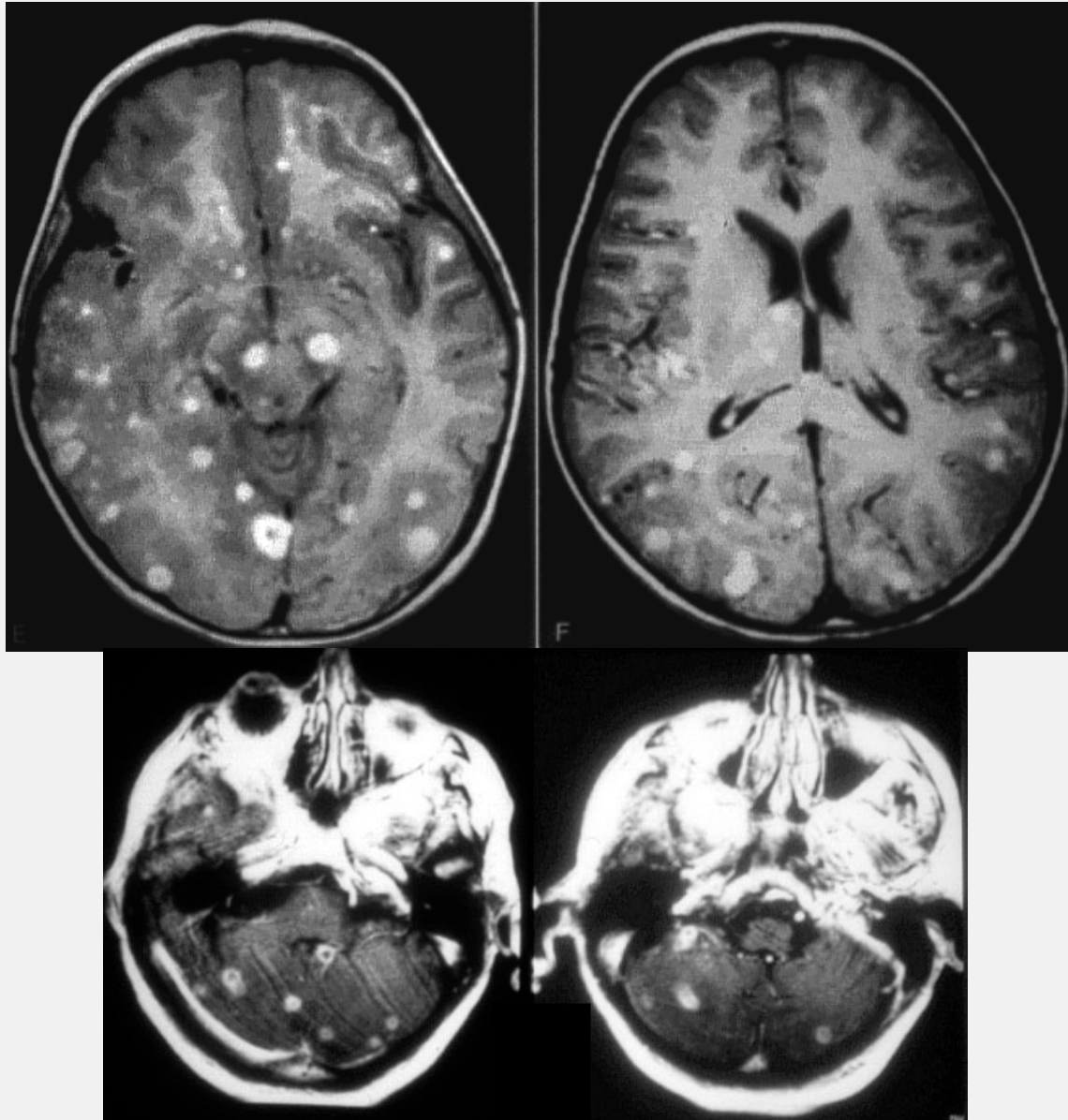
DIFFUSION



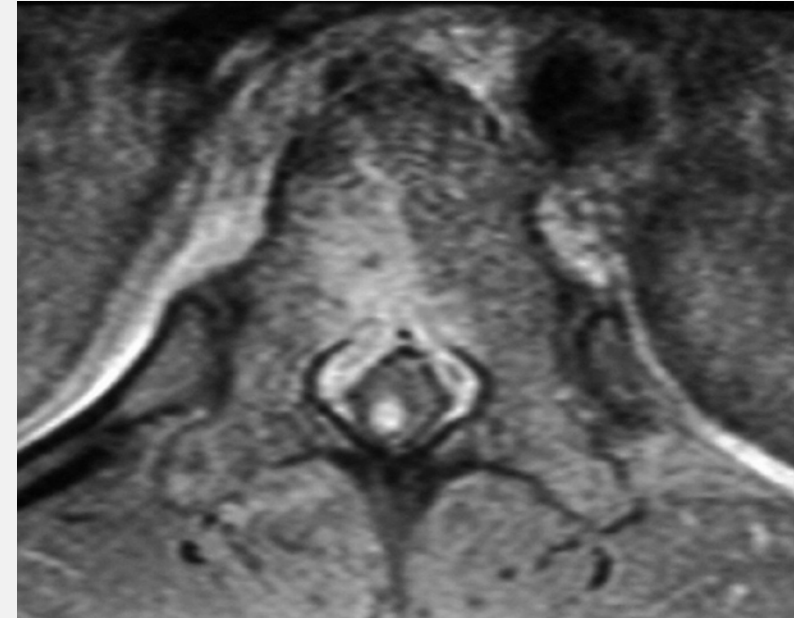
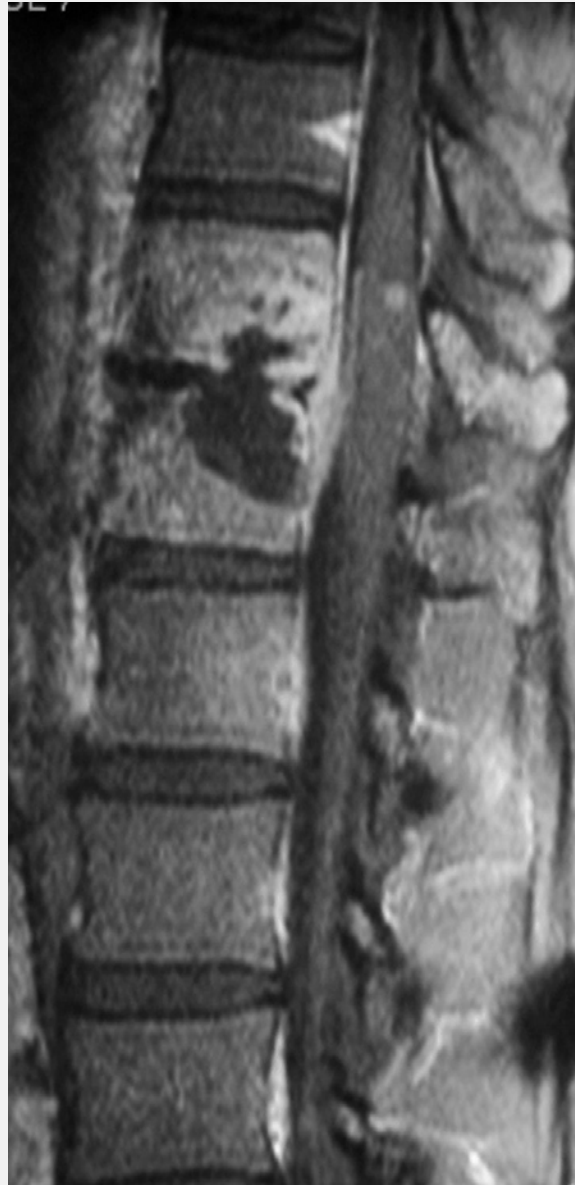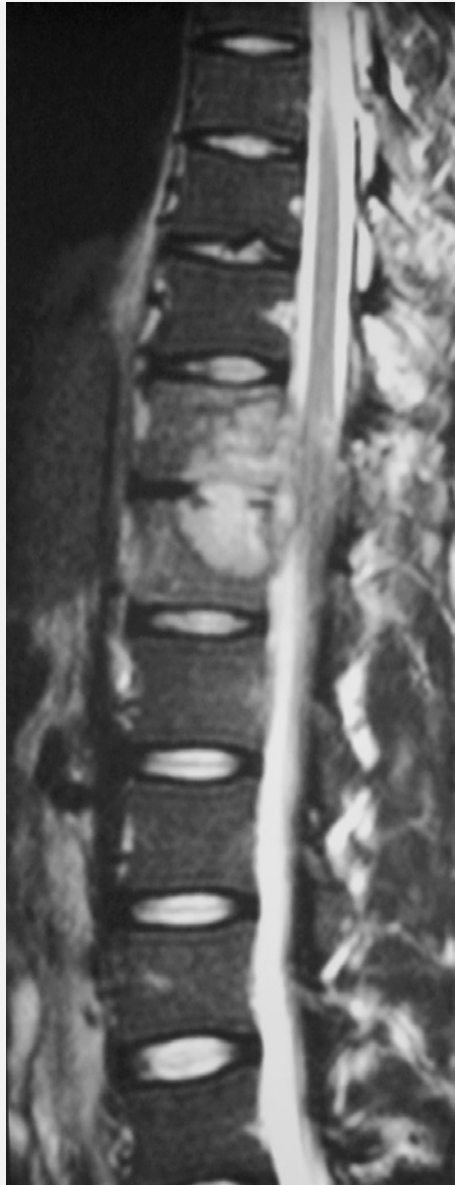Pas de restriction de diffusion !
... comme les Tumeurs

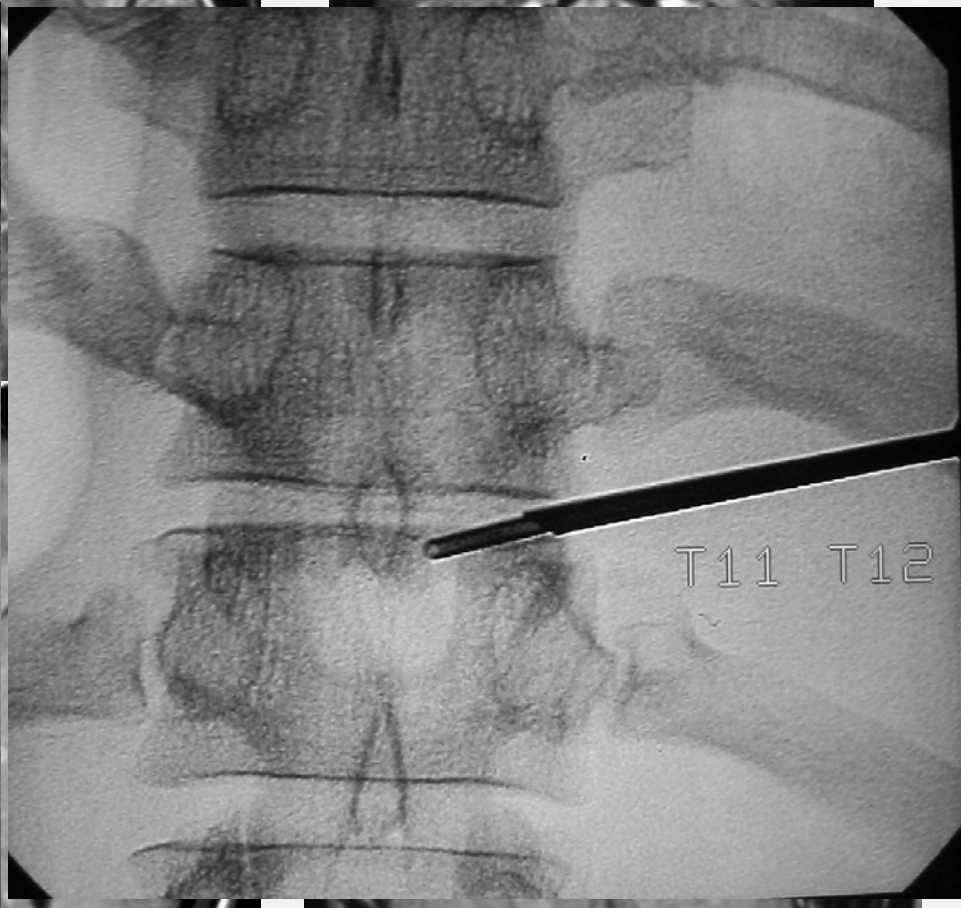
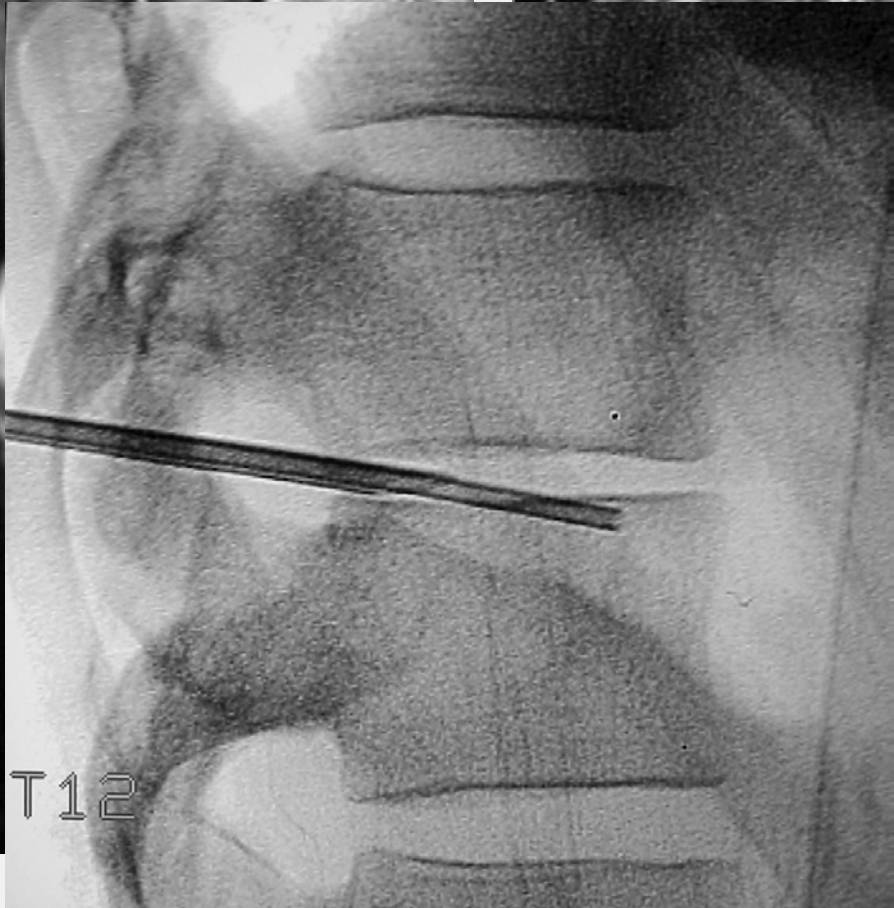
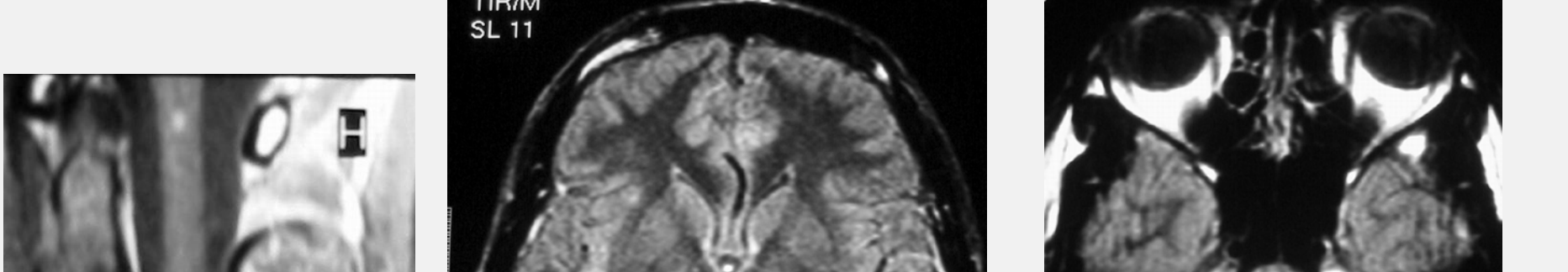


Hemorrhage under treatment

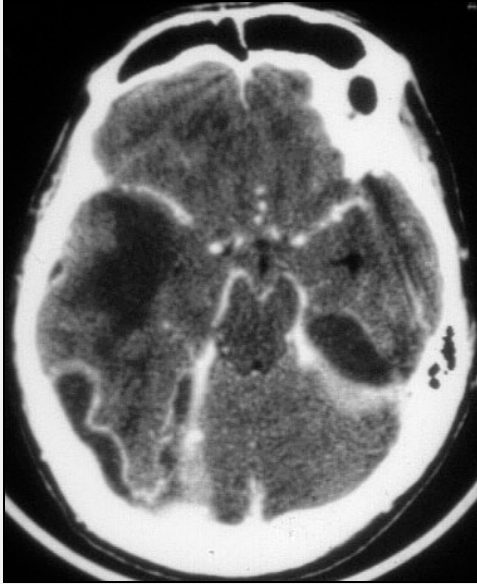


M 19 yo – Lumbar pain - Fever

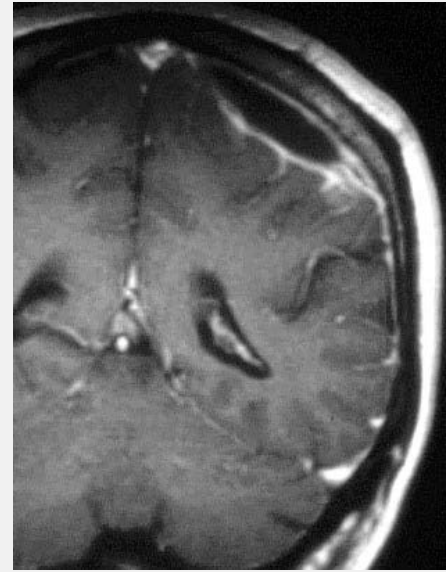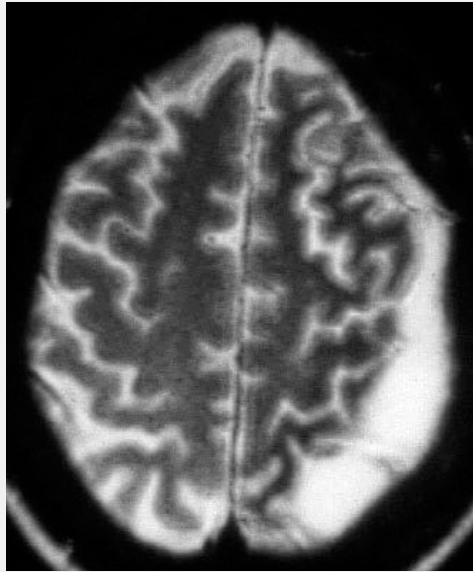
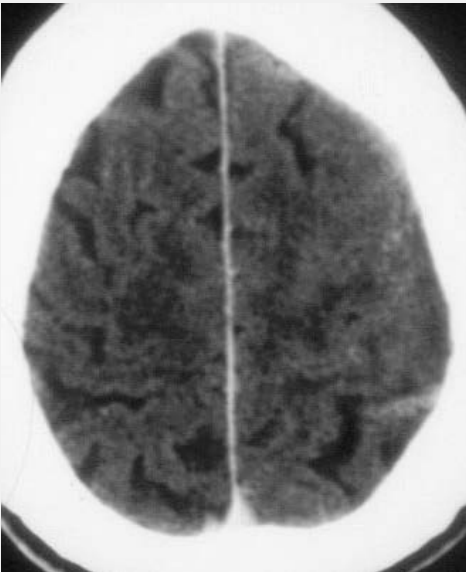




Miliary Tuberculosis

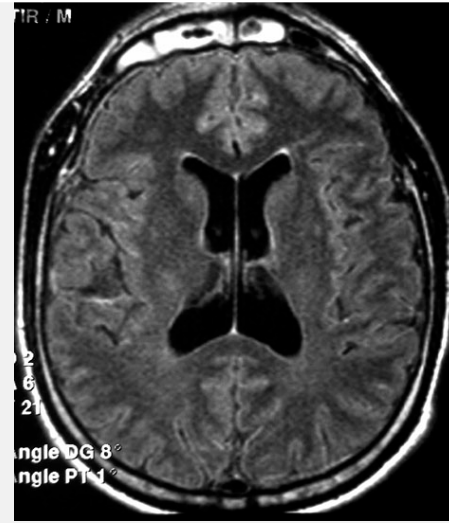
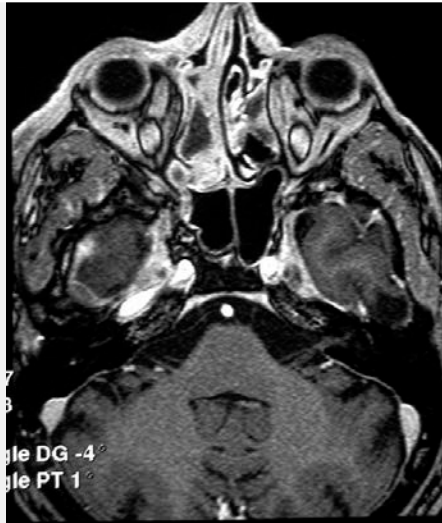

Sub-Dural Empyemas

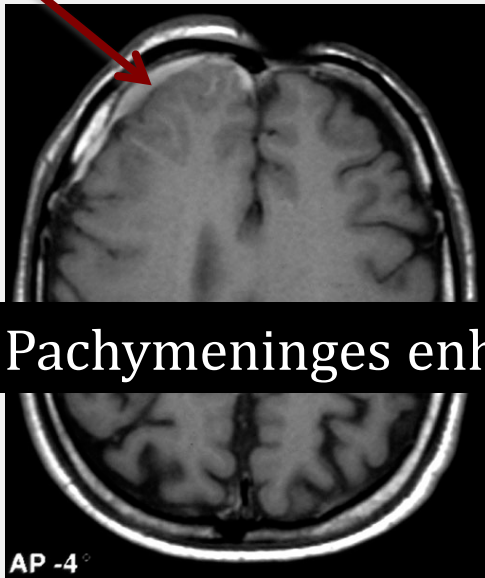


6 Emphyème Sous-Dural

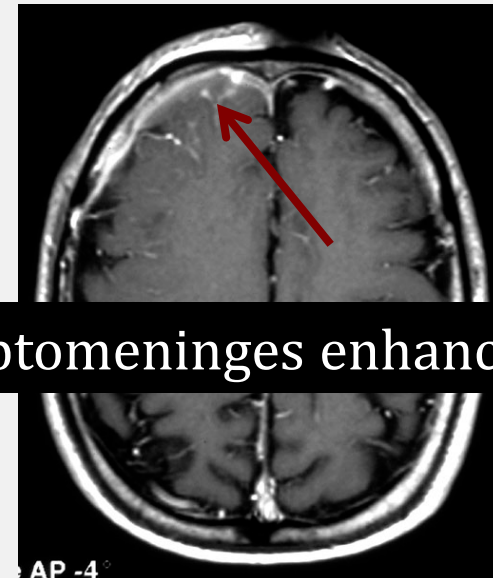
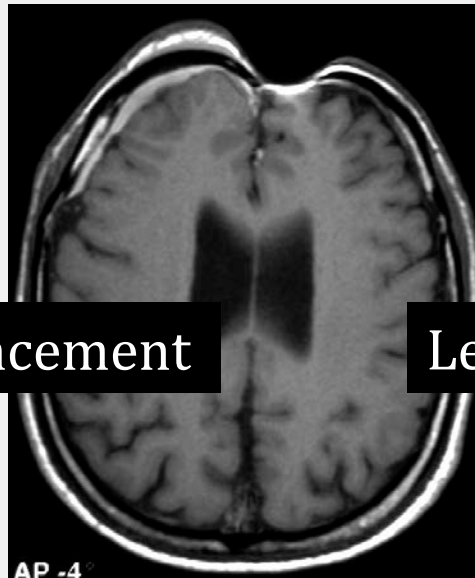
24 y.o,
Chronic
Sinusitis
- Epilepsia



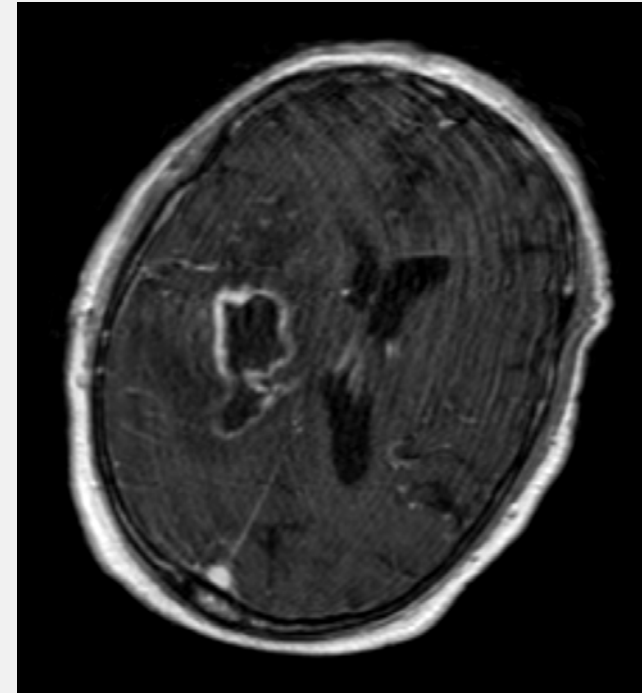
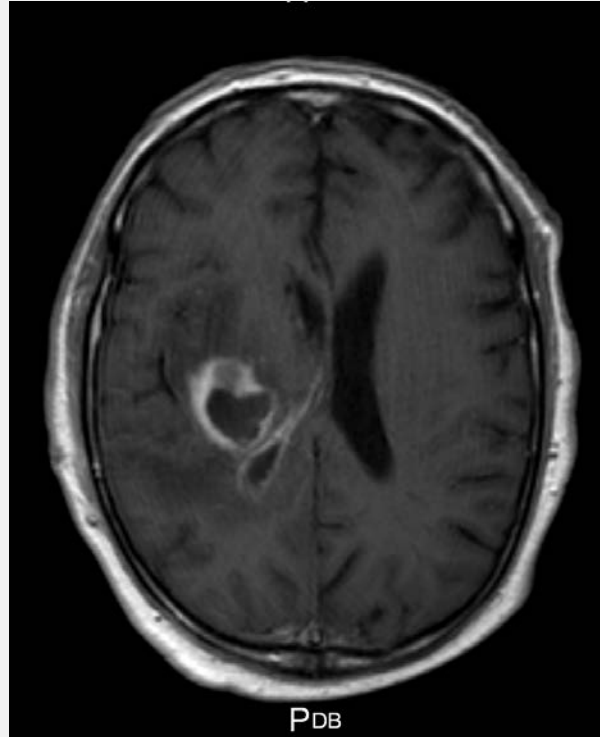
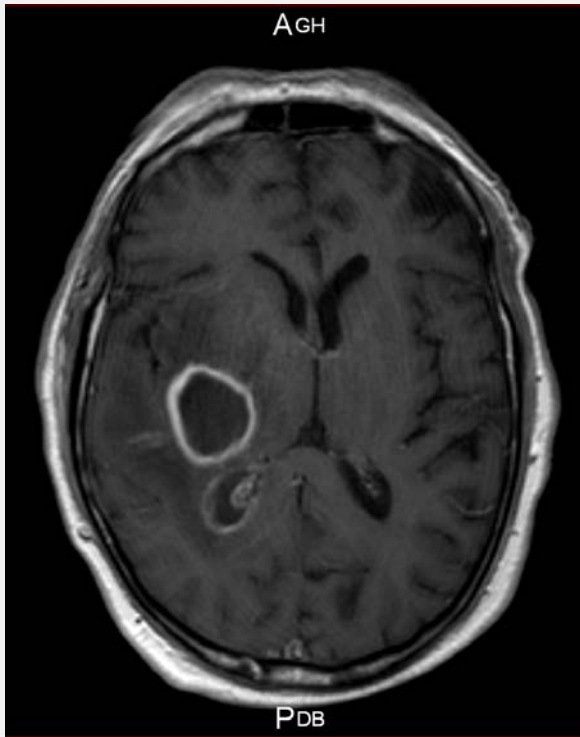
Sub-dural Emphyema



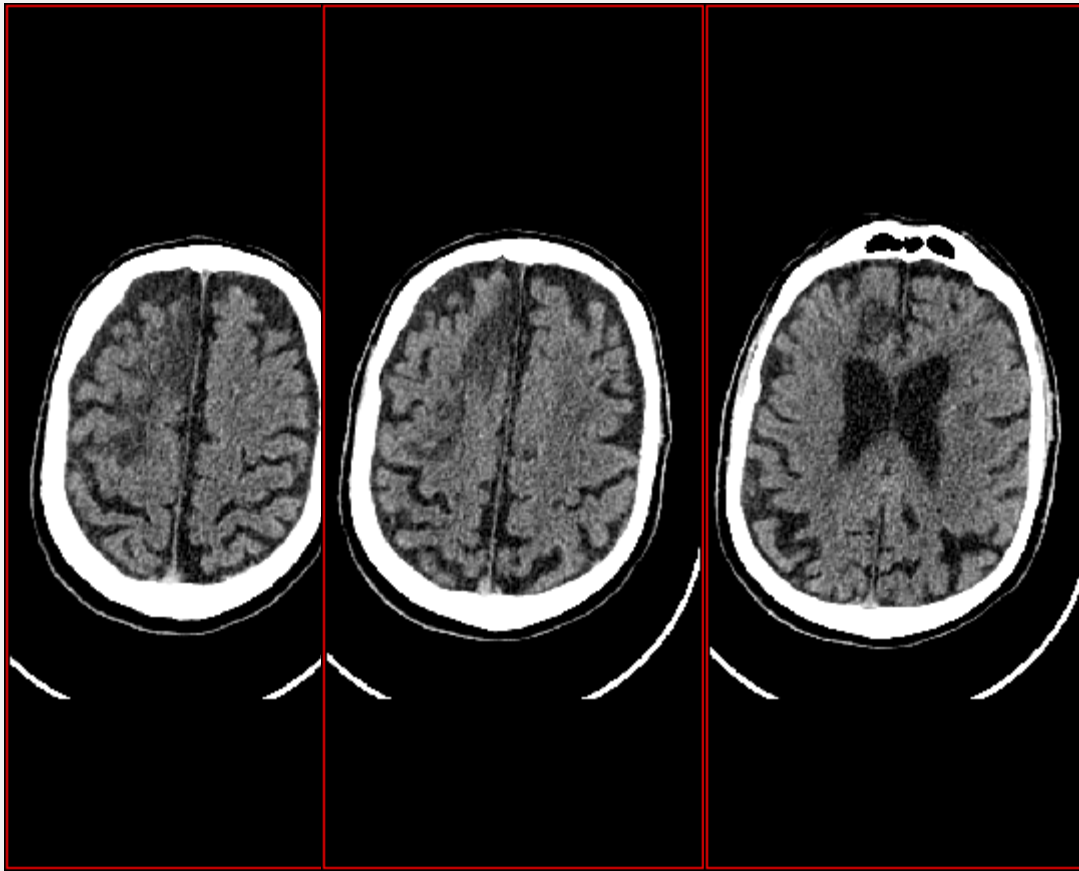
Pachymeninges enhancement



Leptomeninges enhancement



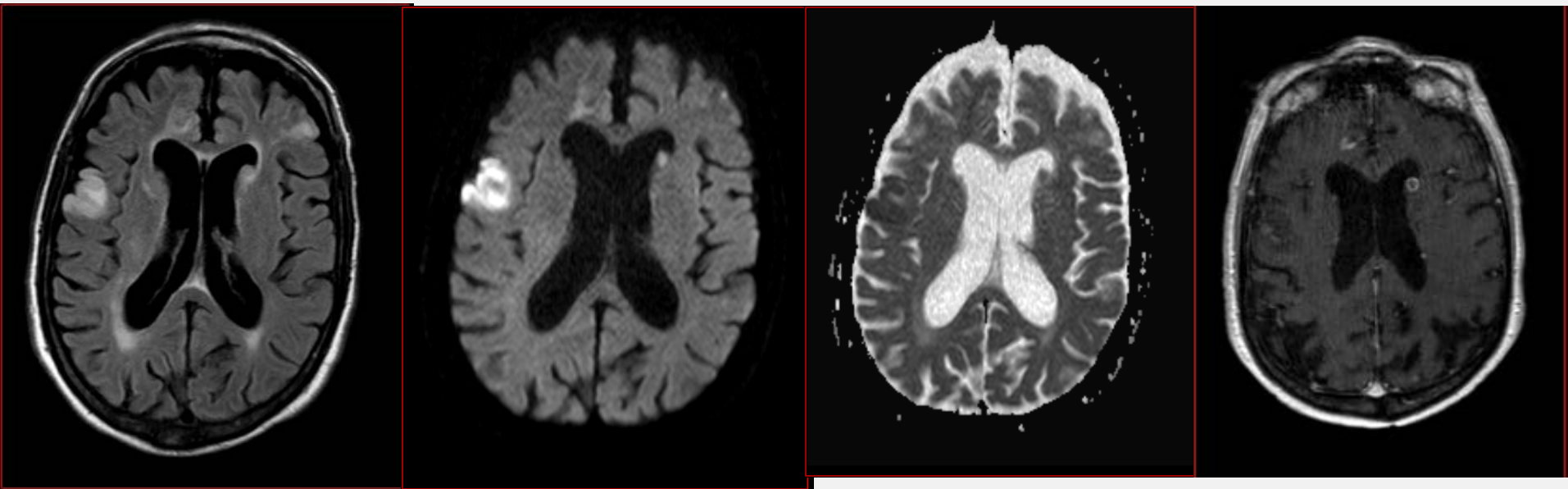
- Patient de 63 ans
- Hospitalisé pour érysipèle du MI gauche
- Puis déficit moteur hémicorporel droit



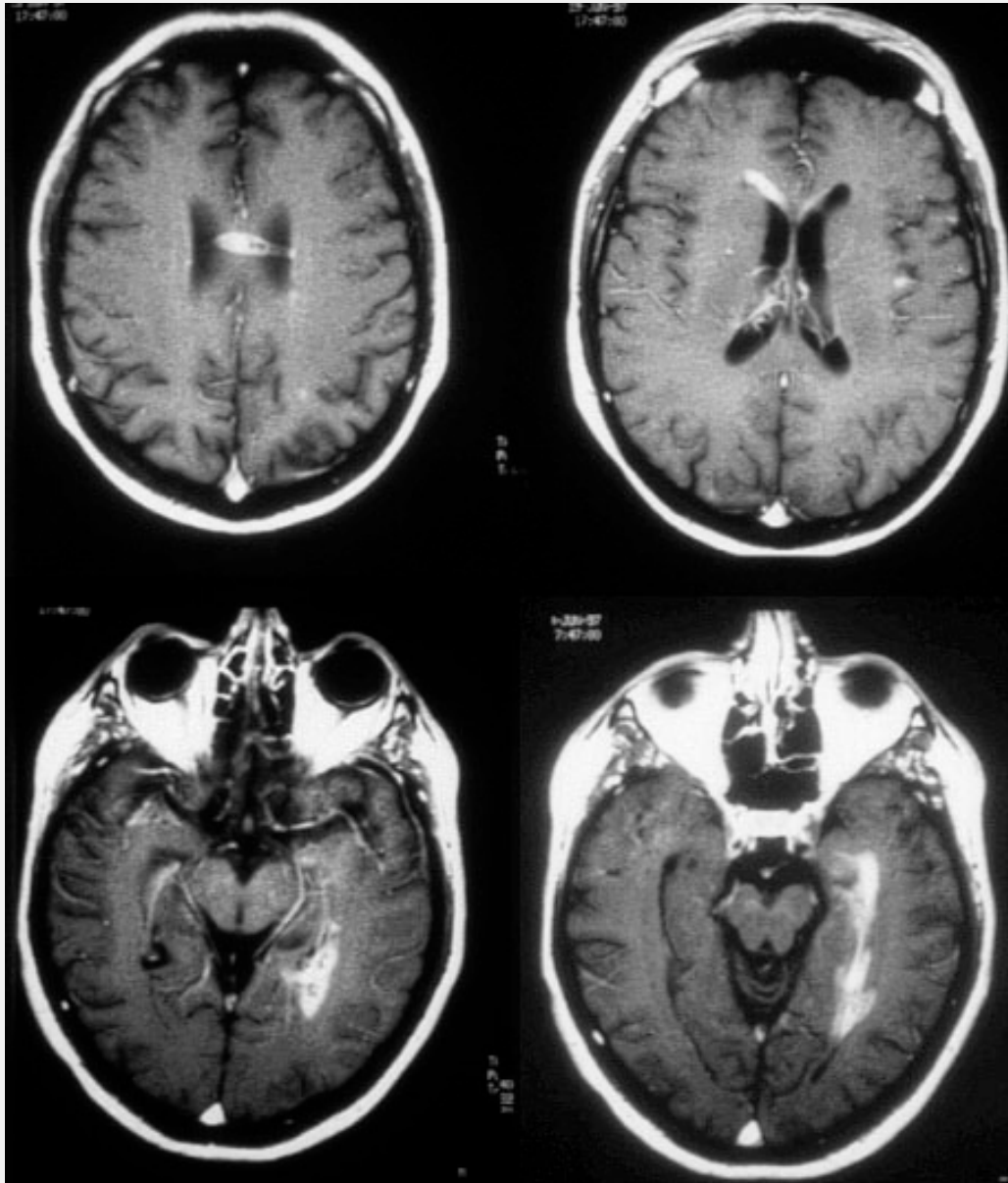
- IRM :

Diffusion

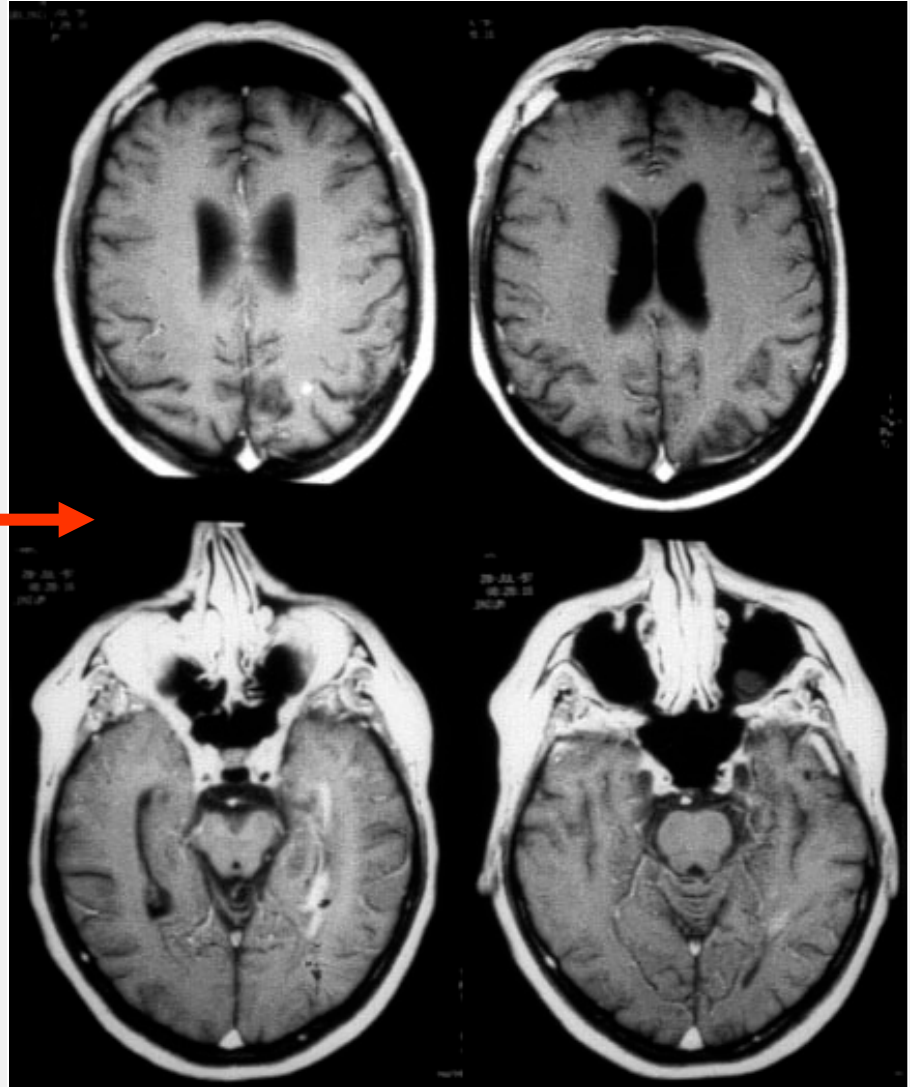
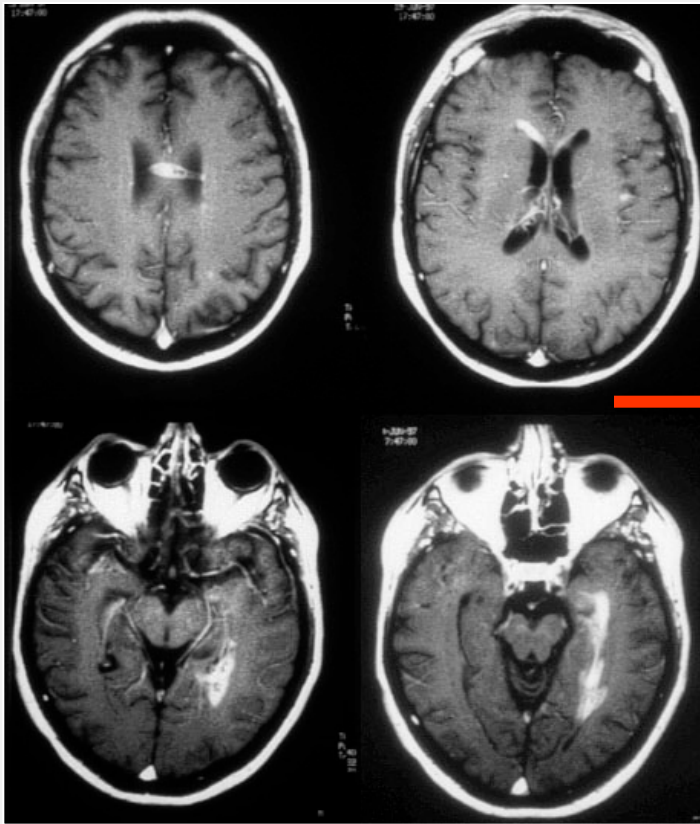
ADC



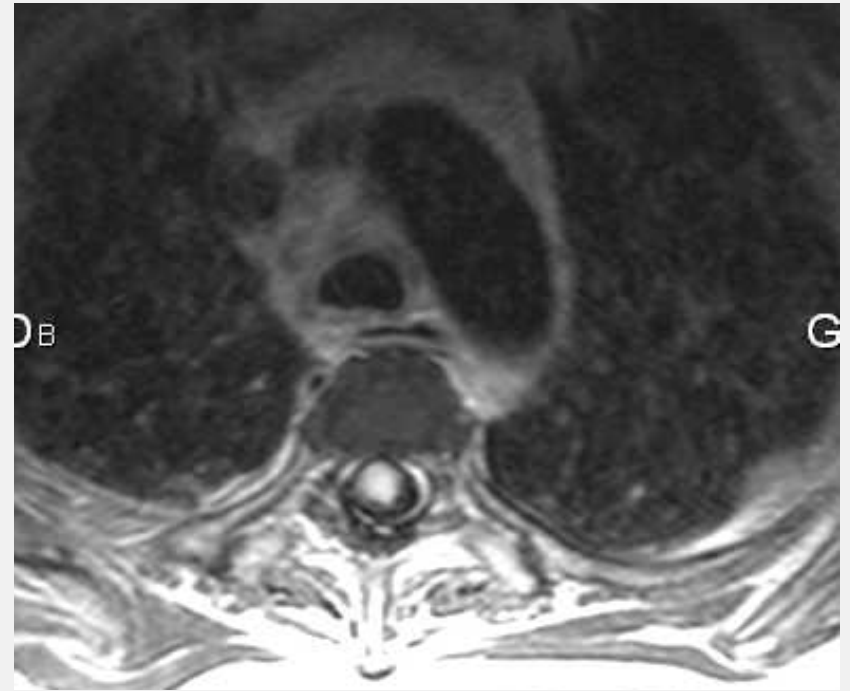
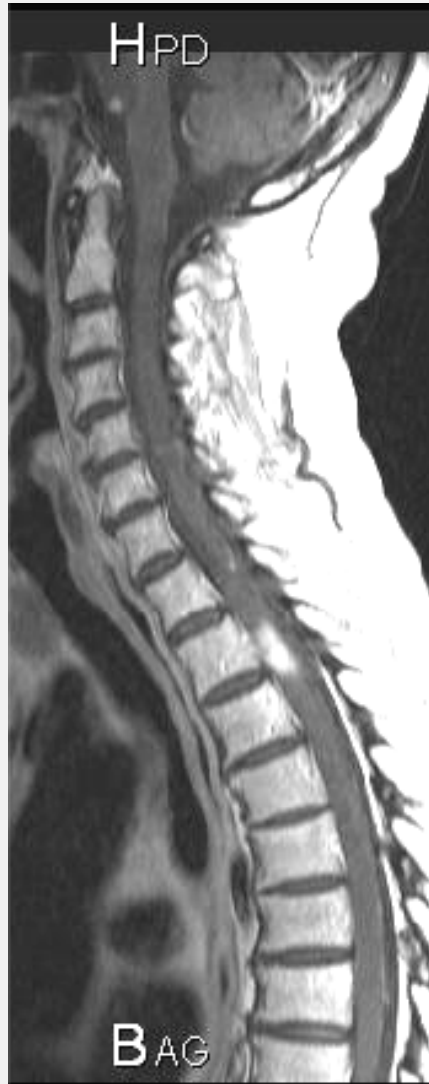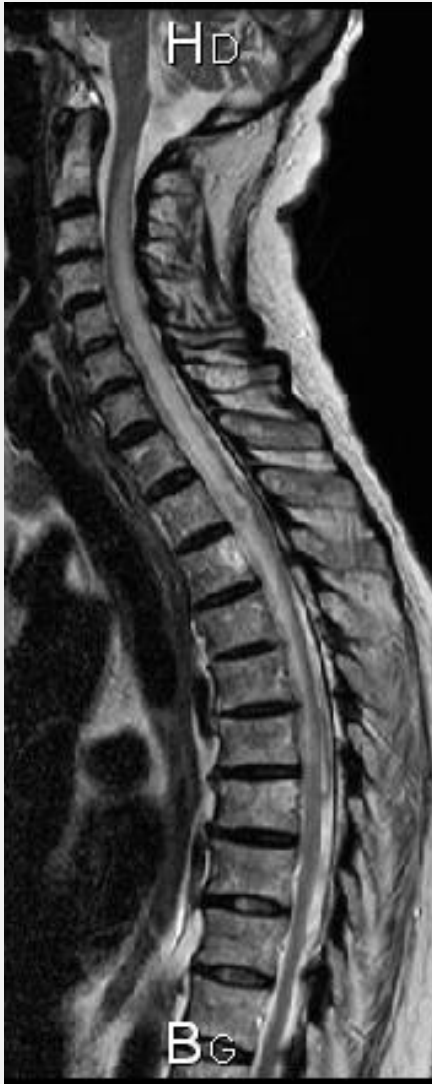Endocardite Infectieuse



Après 4 semaines d'antibiothérapie anti-toxoplasmique

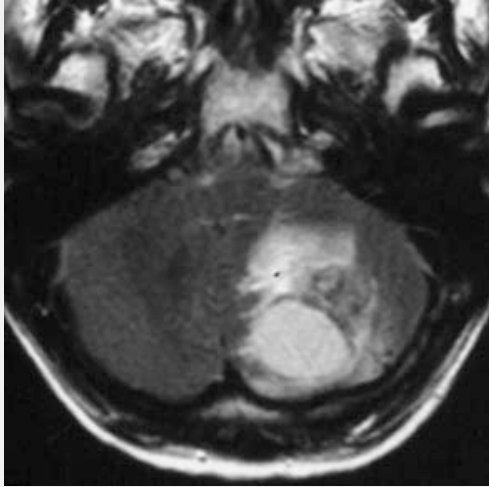


Imaging is an emergency to rule out cord compression

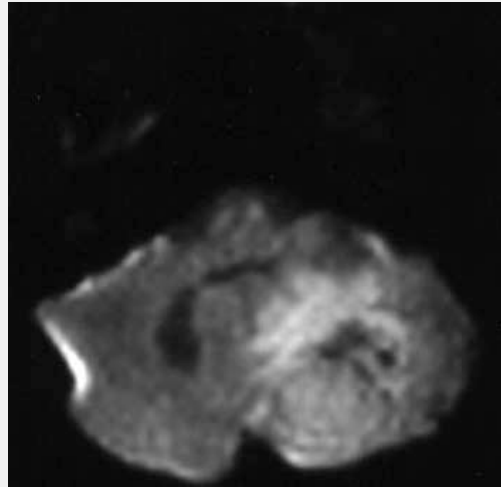


Spinal Cord Abscess

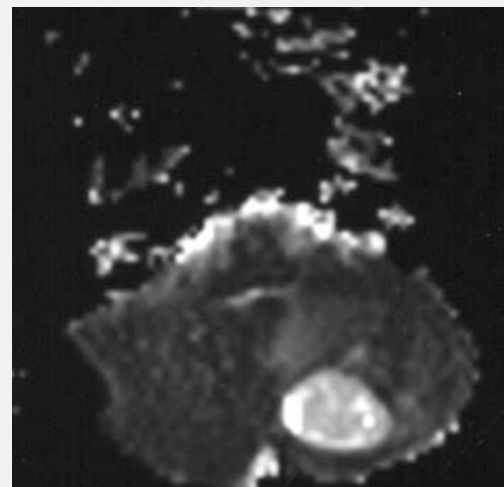
8 Non ce n'est pas un Abcès !



FLAIR

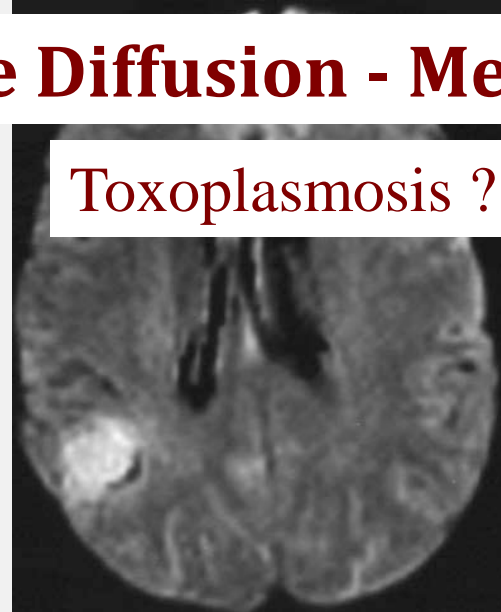
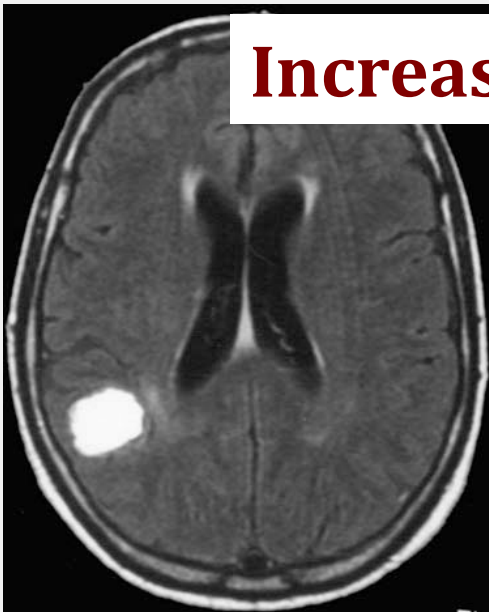

DIFFUSION

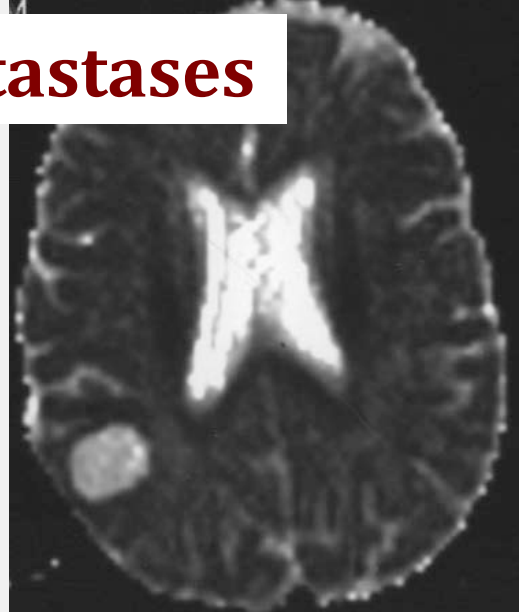


ADC

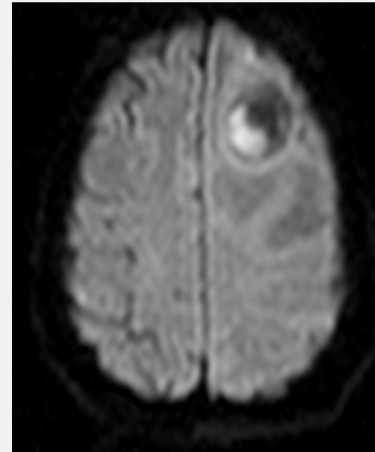
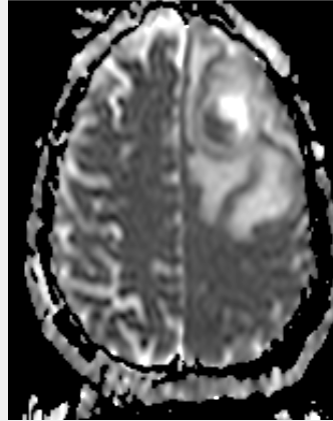
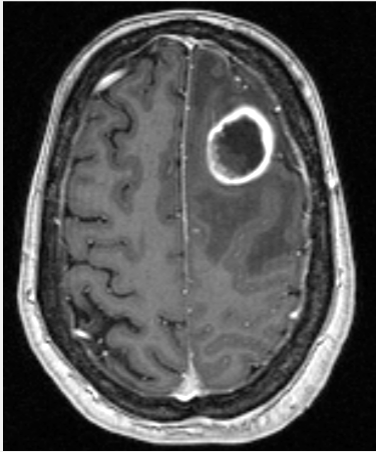
Increase Diffusion - Metastases




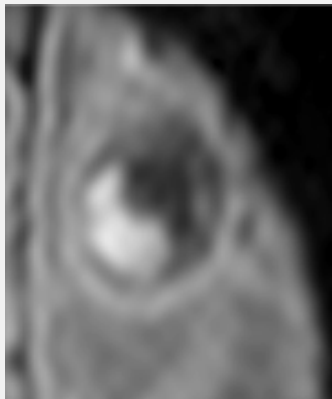
Toxoplasmosis ?



8 Non ce n'est pas un Abcès !



ADC

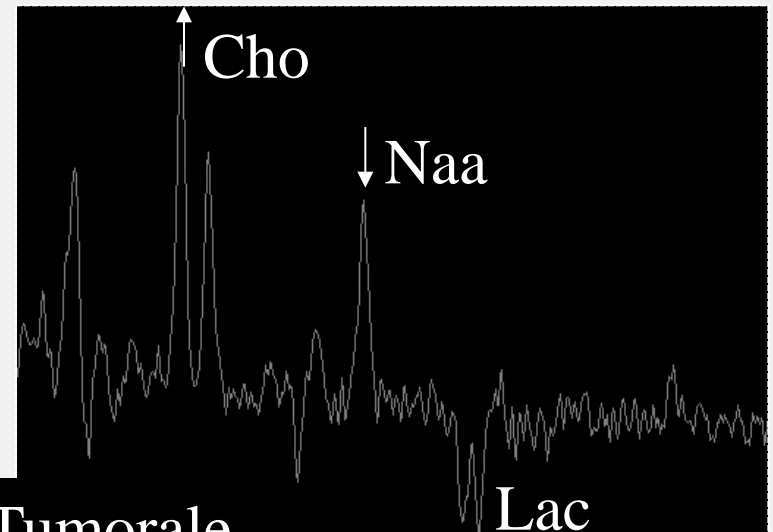
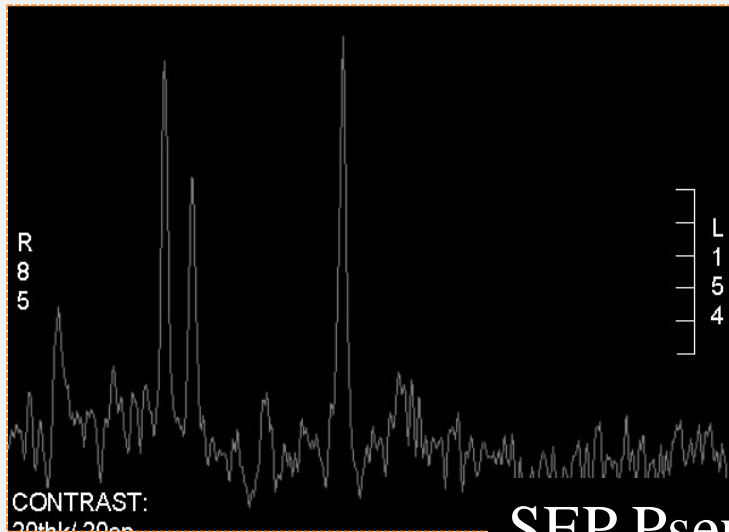
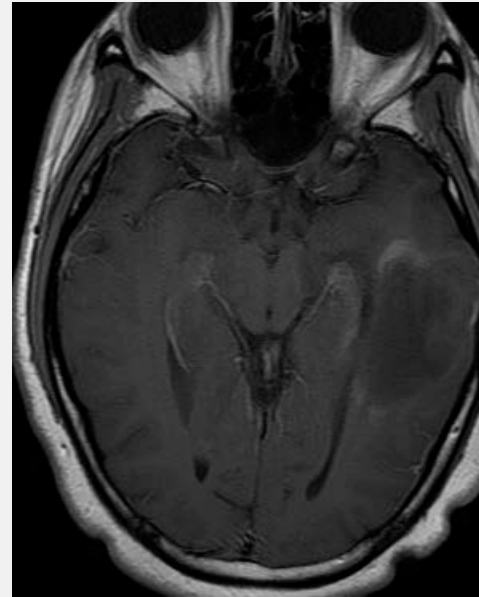
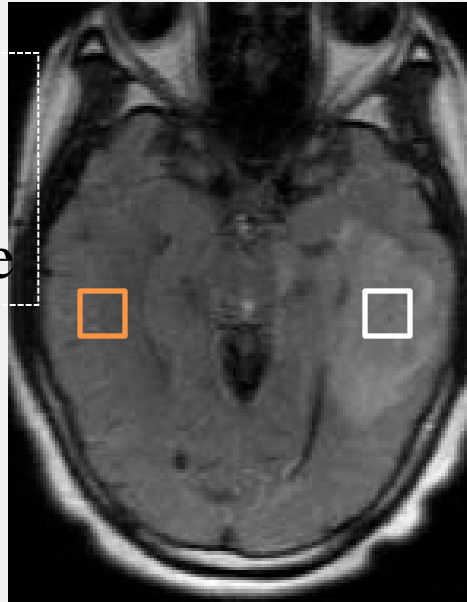


???

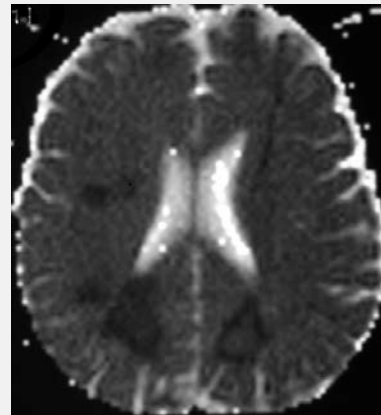
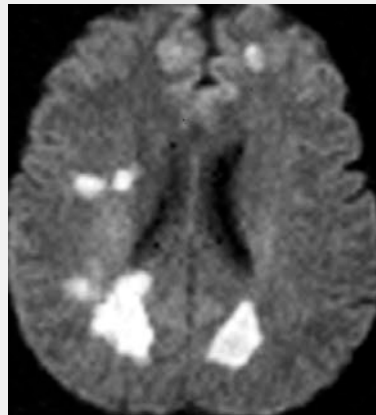
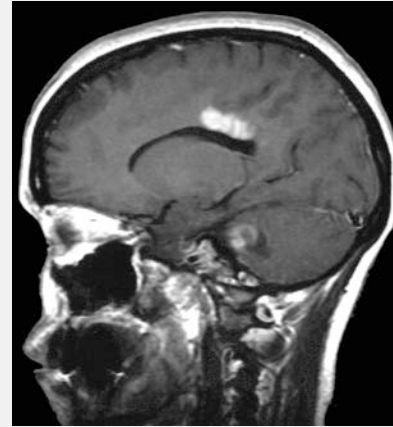
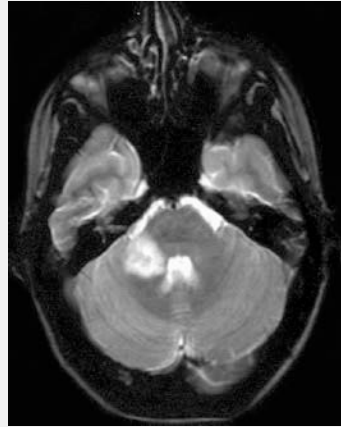
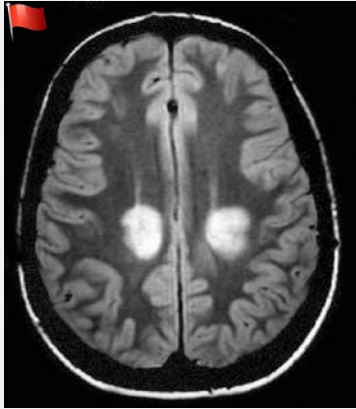Métastase, contenu hétérogène hémorragique

8 Non ce n'est pas un Abscès !

-Jeune femme
de 25 ans
-Crise comitiale

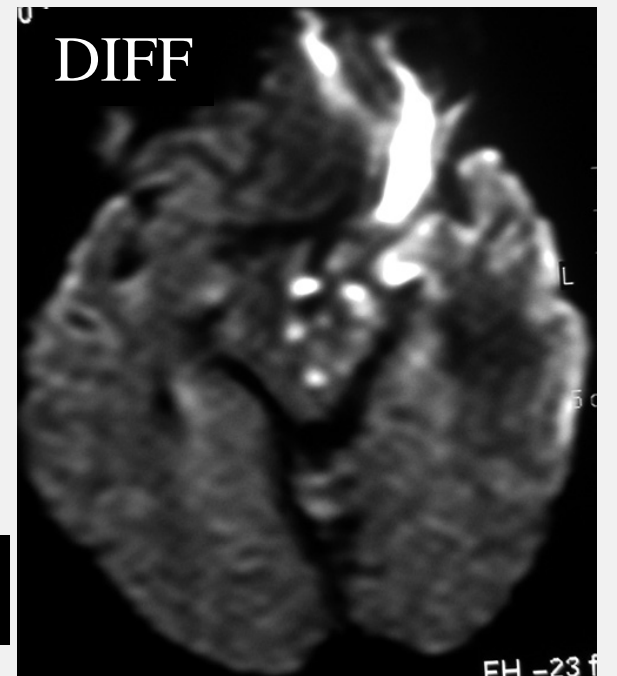
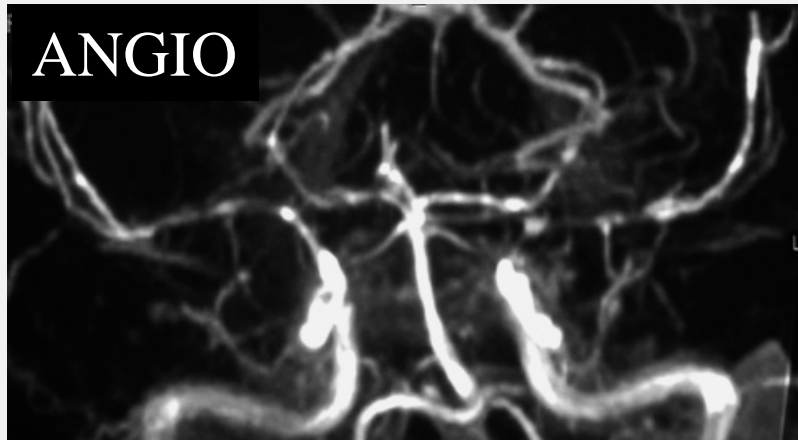
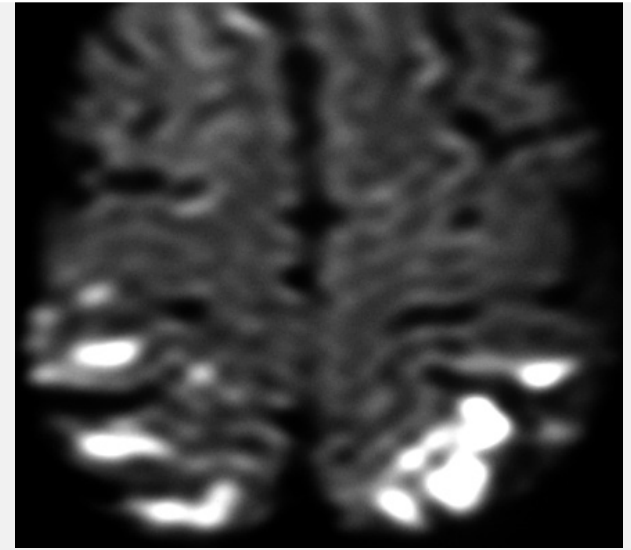
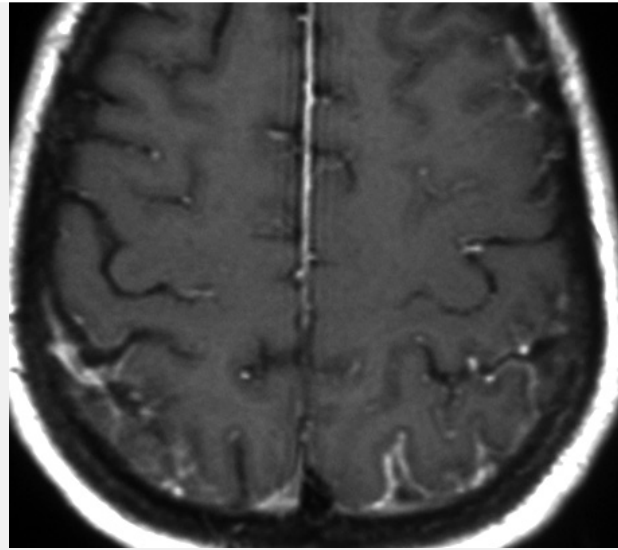
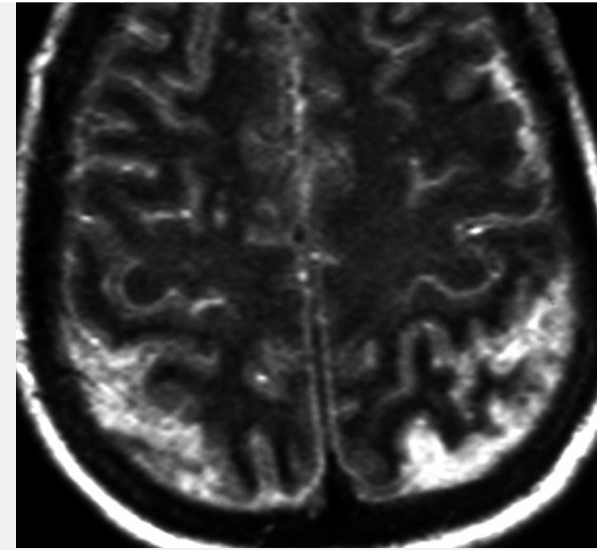


SEP Pseudo-Tumorale

ADEM

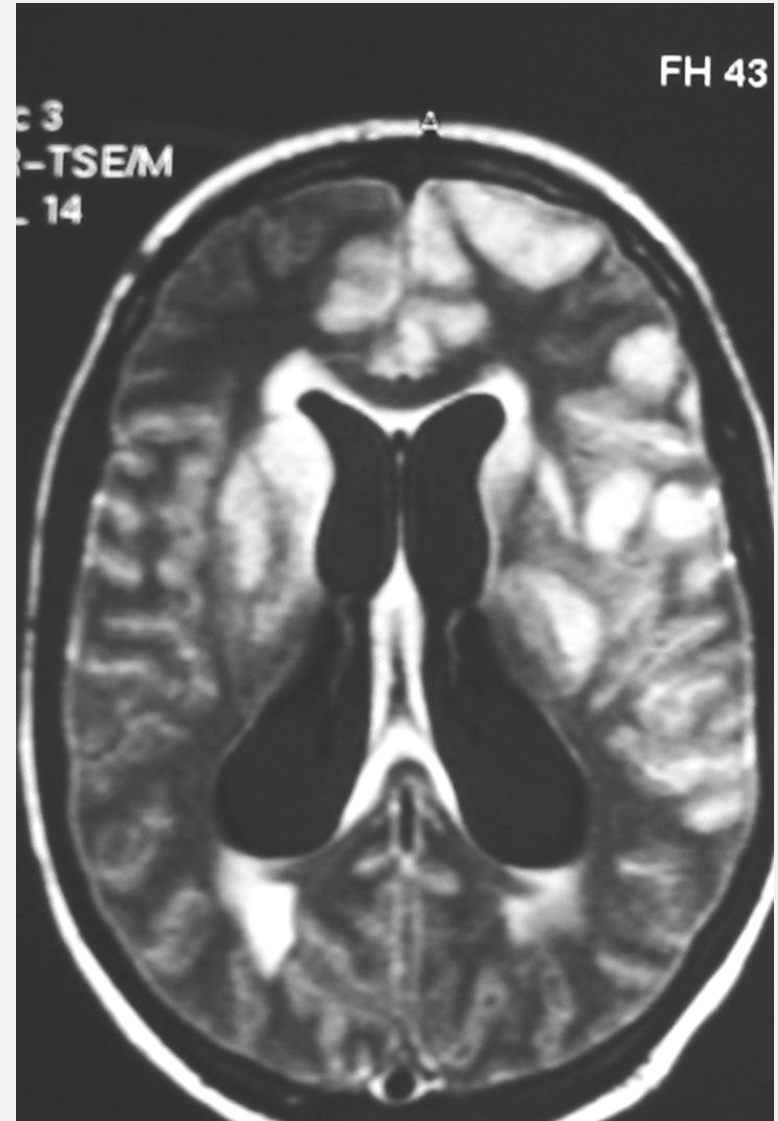
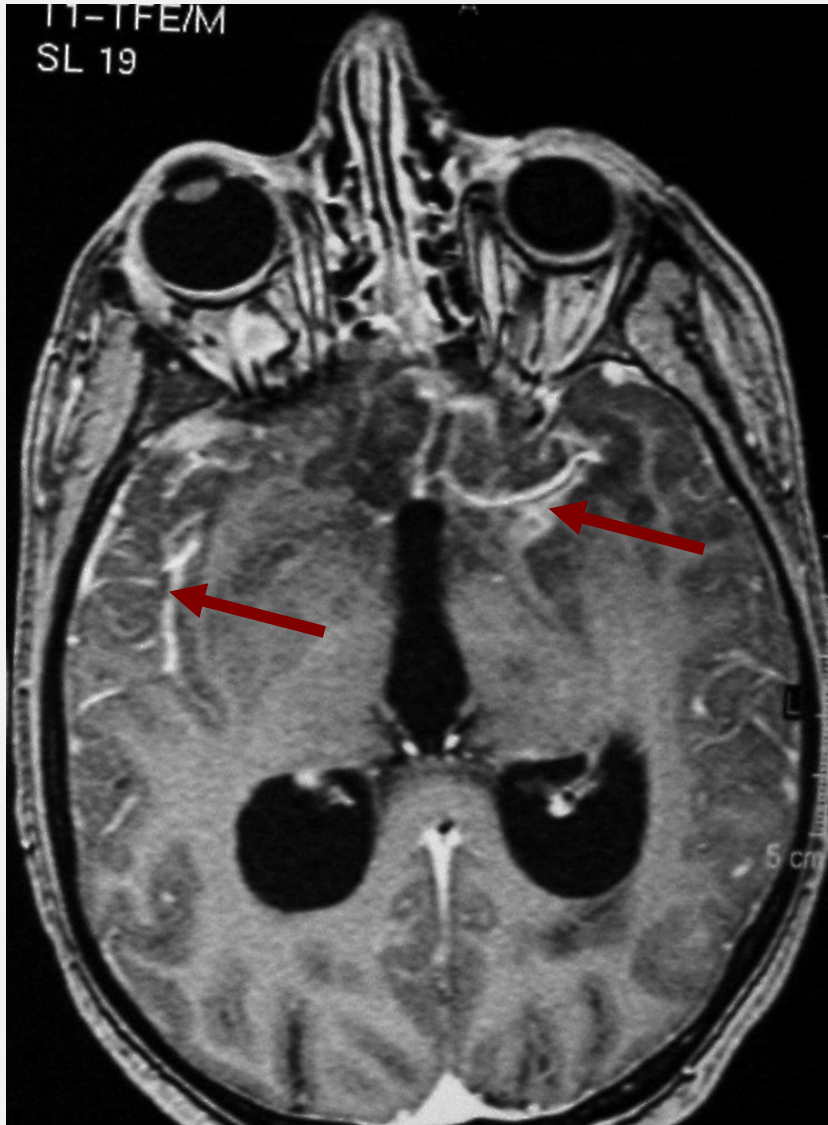
ADC

8 Non ce n'est pas un Abscès !

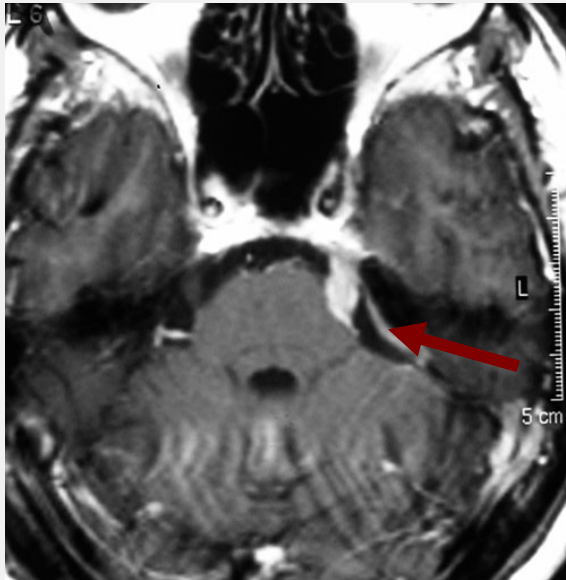
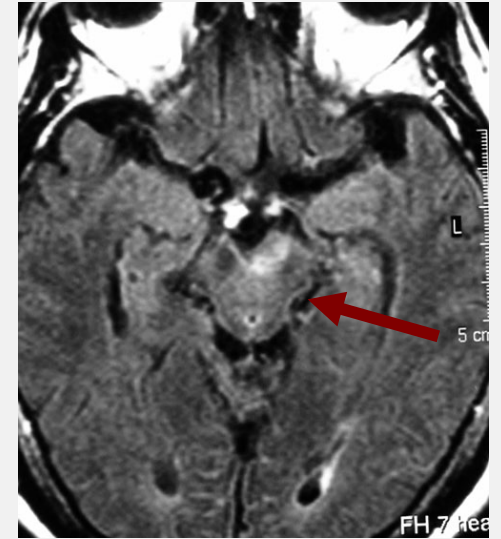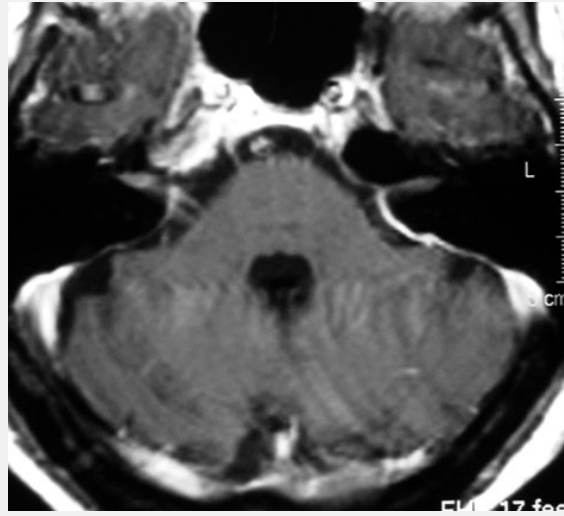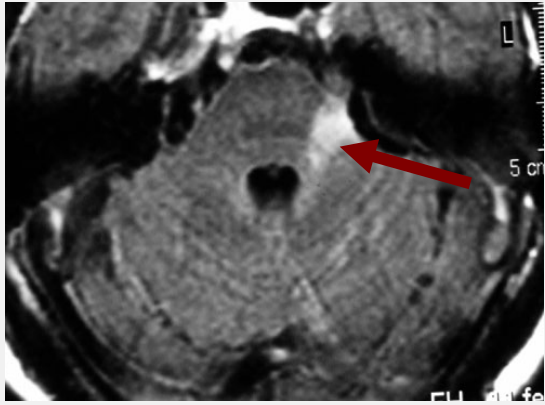


Complications d'une Méningite Pneumo

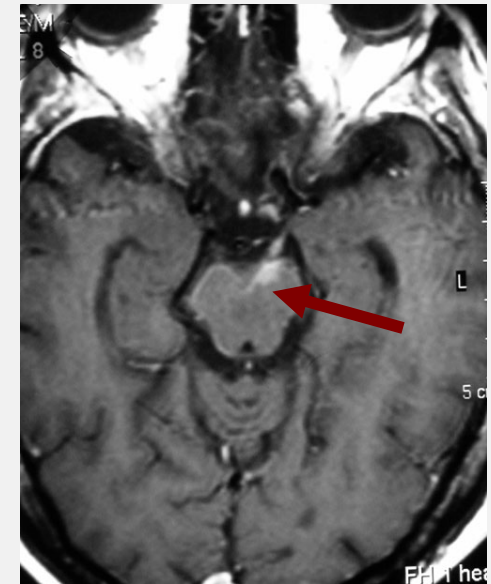
8 Non ce n'est pas un Abscès !



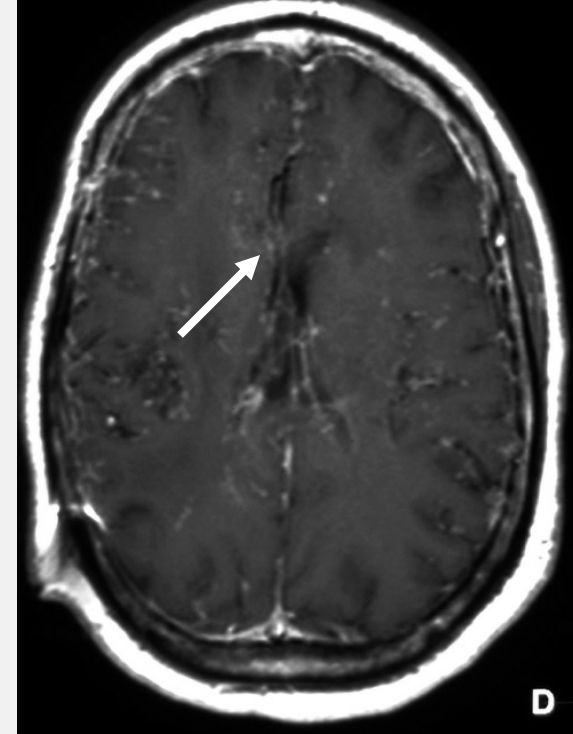
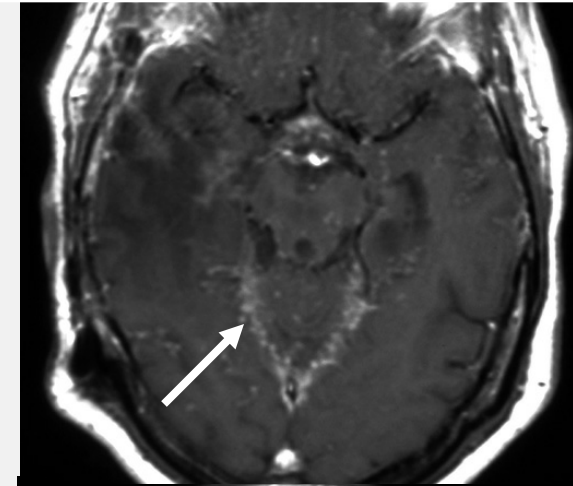
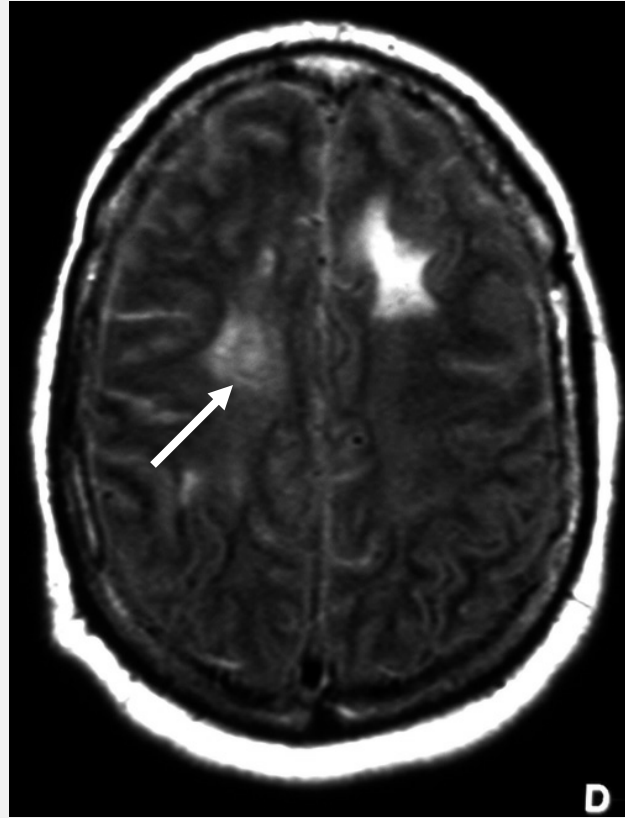
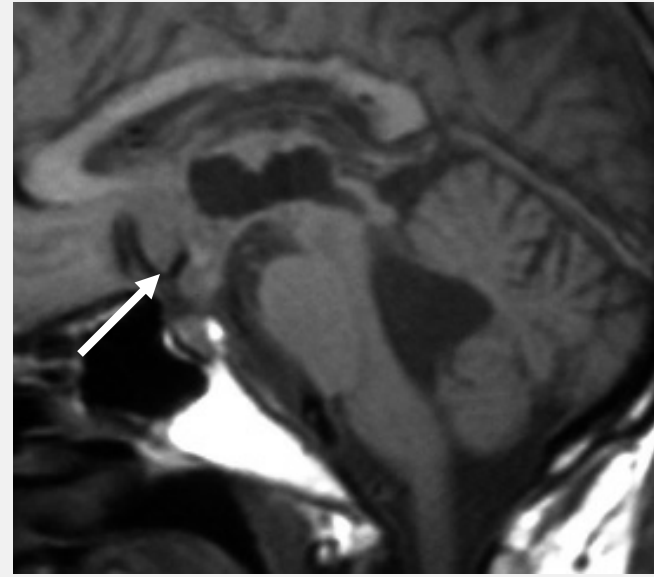
8 Non ce n'est pas un Abcès !



PL =
Meningeal
Lymphoma



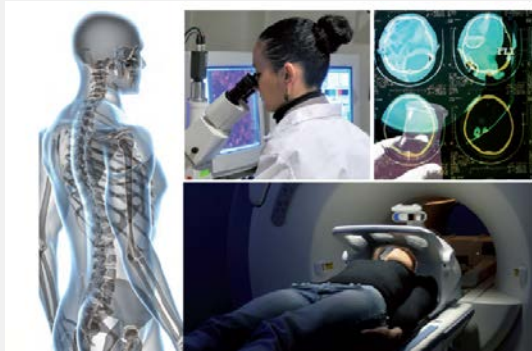8 Non ce n'est pas un Abscès !



Sarcoidose

Parasites (Cysticercosis, Multilocularis, ...)
Mycotic agents (Aspergillus, Cryptococcus, ...)
Bacteria (Lyme, Listeria, ...)
Virus (HIV, CMV, EBV, ...)

...



TRAIL
Translational **R**esearch and
Advanced **I**maging **L**aboratory
<http://trail.labex-univ-bordeaux.fr/>